

# Graft-versus-Host Disease: How it Affects Skin

**Celebrating a Second Chance at Life  
Survivorship Symposium**

May 3-9, 2025



**Alina Markova, MD**  
**Memorial Sloan Kettering  
Cancer Center**

# Graft-versus-Host Disease of the Skin, Hair, and Nails

Alina Markova, MD  
Dermatologist

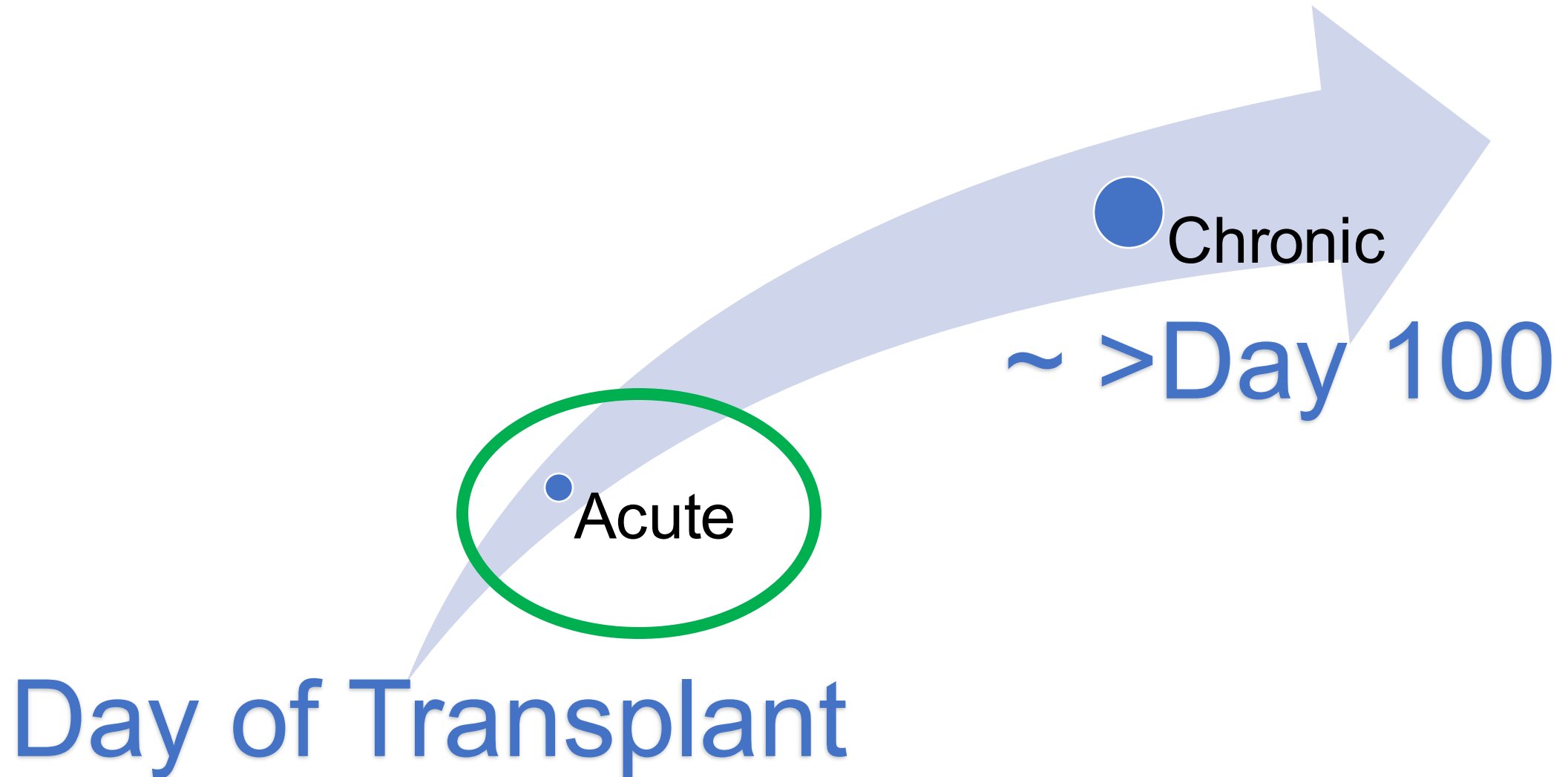


# GVHD of the Skin, Hair, and Nails: Learning Objectives

1. Understand the various ways chronic GVHD can affect the skin, hair, and nails
2. Review the timeline of manifestations of cGVHD on the skin, hair and nails
3. Describe how cutaneous GVHD of the skin, hair, and nails can affect activities of daily living
4. Summarize pharmacological and non-pharmacological therapies that can help patients who have cutaneous GVHD

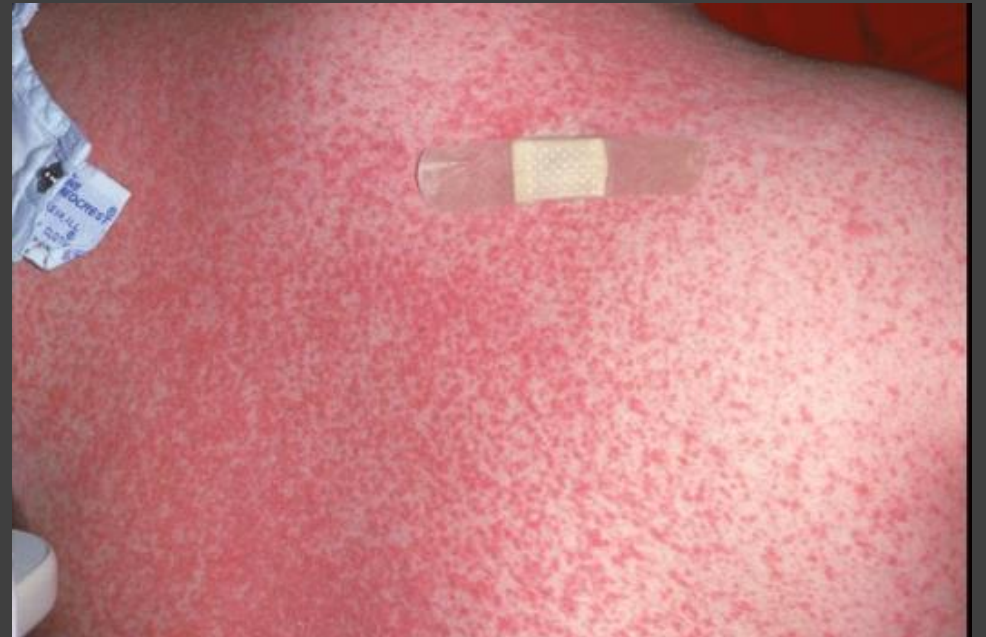
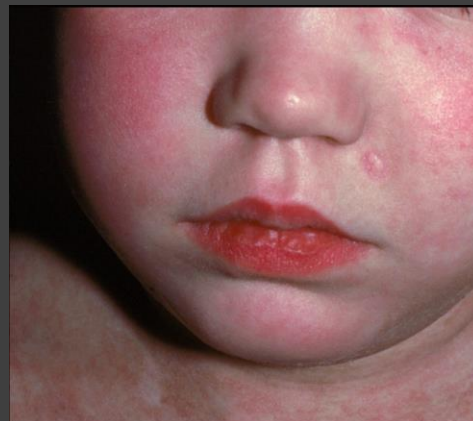
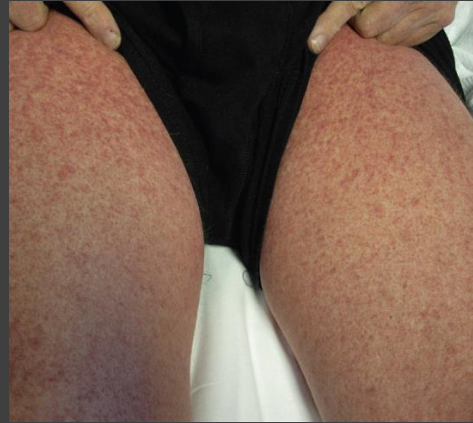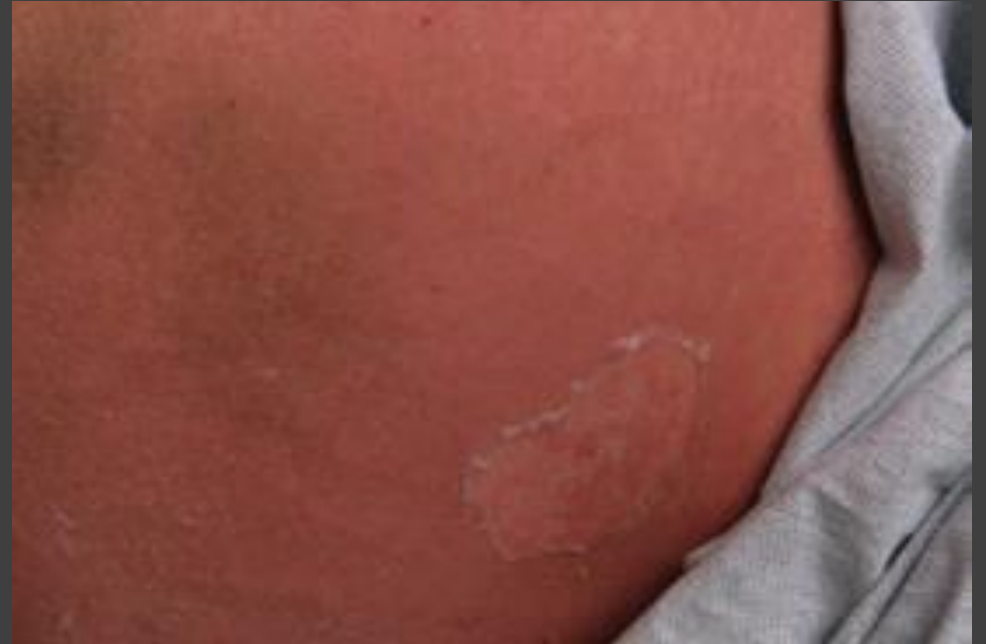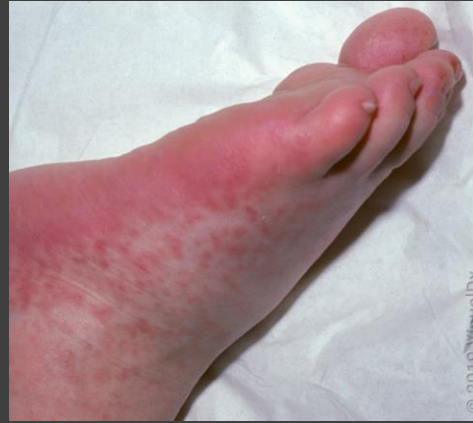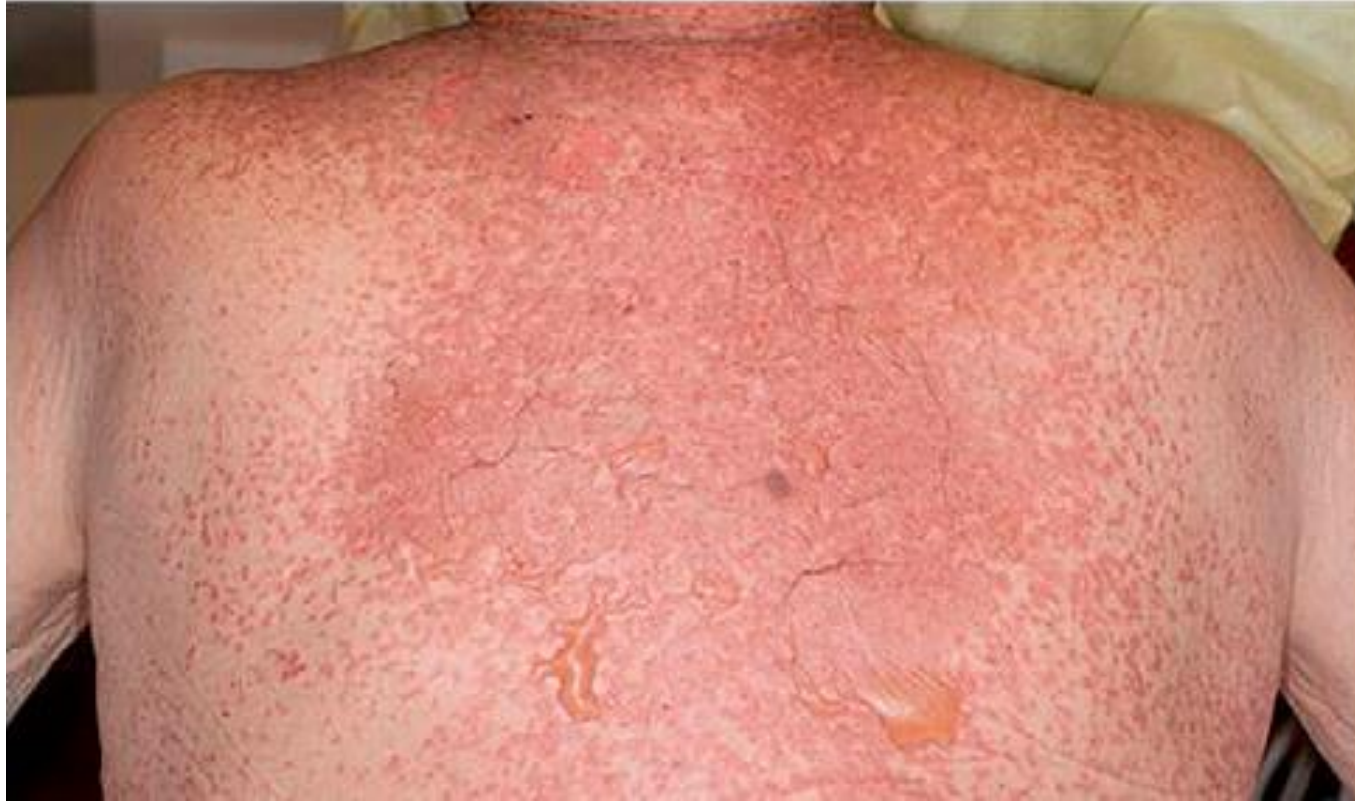There are two presentations of skin GVHD



# Acute GVHD of the skin

- ~First 100 days
- Pink, flat and raised areas
- May be itchy





*J Am Acad Dermatol 2012;66:515.e1-18*

# Severity of acute GVHD of the skin is determined by the % of involved skin

Stage	Skin (% body surface area of active areas only)
0	0
1	<25
2	25-50
3	>50
4	>50% blister formation and peeling >5% BSA

Harris AC, et al. Biol Blood Marrow Transplant.



# Acute GvHD of the skin: Topical approach to therapy

Topical  
corticosteroids


Topical  
calcineurin  
inhibitors

NBUVB  
phototherapy





# Topicals come in different vehicles



# Topical Therapies for Acute GVHD of the Skin

Localized

- **Topical steroids twice daily**
- **Topical calcineurin inhibitors twice daily**



Widespread


- **Systemic therapy as per BMT**
- **Narrowband ultraviolet B phototherapy (off-label)**



# Find a Phototherapy Center at [aad.org/fad](https://aad.org/fad)

[About AAD](#) [Contact us](#) [Support AAD](#) [Media](#) [AAD store](#) [Employment](#)


 [Alina Markova](#)  [Cart](#)

 **AMERICAN ACADEMY of DERMATOLOGY | ASSOCIATION**


[Donate](#)

[MEMBER RESOURCES AND PROGRAMS](#) [PRACTICE MANAGEMENT CENTER](#) [EDUCATION](#) [MEETINGS AND EVENTS](#) [ADVOCACY](#) [PUBLIC AND PATIENTS](#)

## Find a Dermatologist

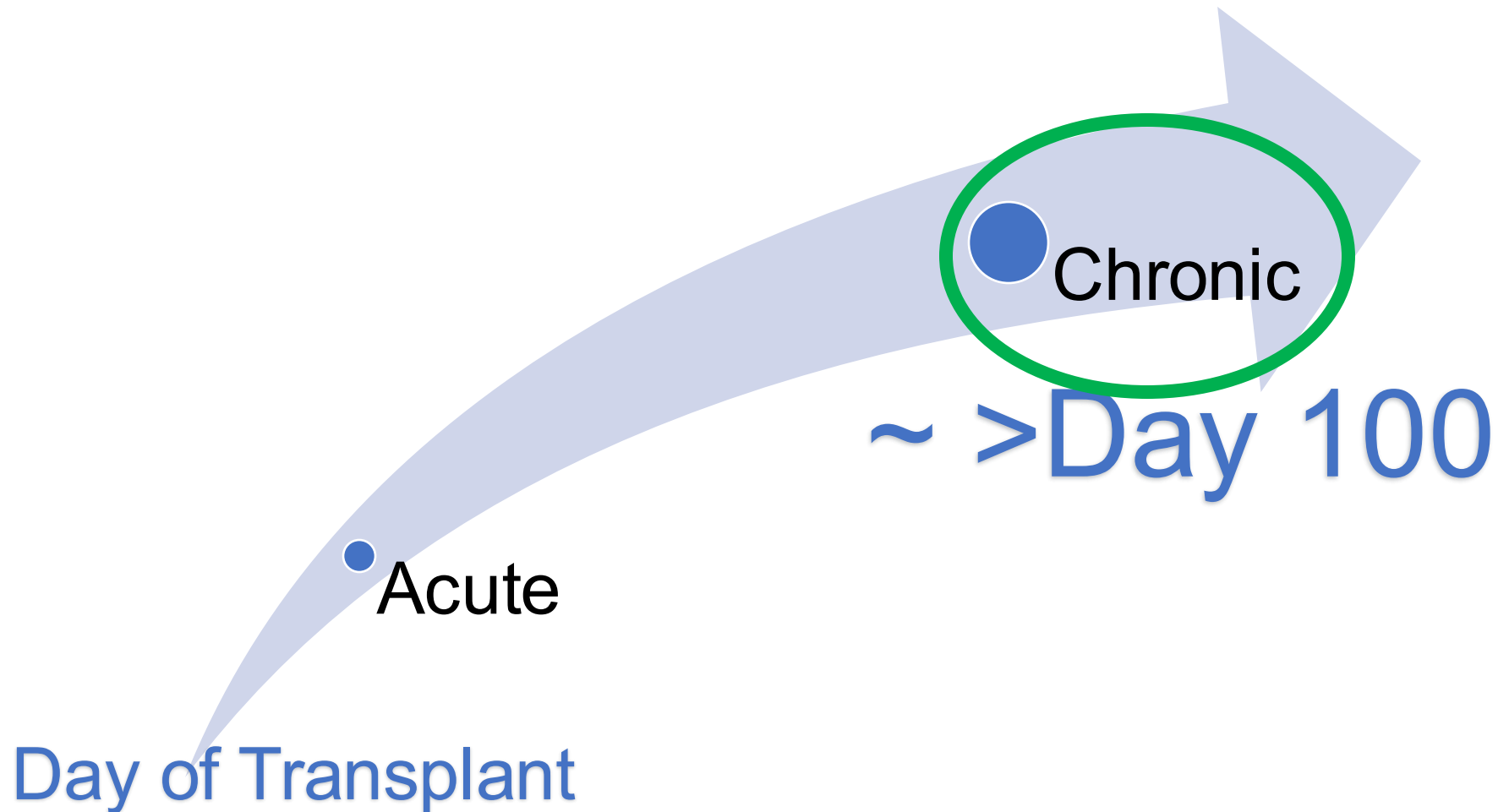
 Sponsored by  **CareCredit**  
Making care possible...today.

[Why see a dermatologist? Learn more.](#)

 You are signed in to the member directory

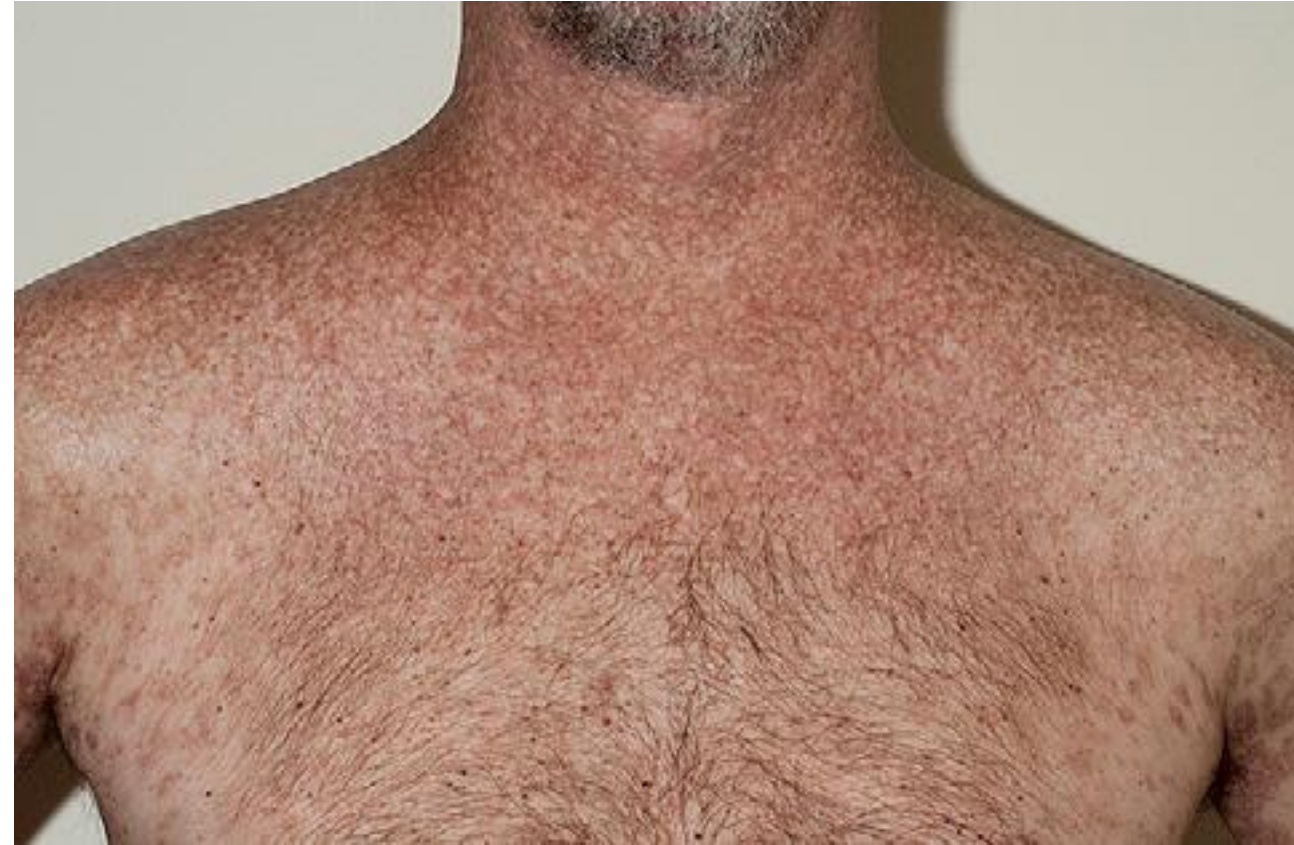
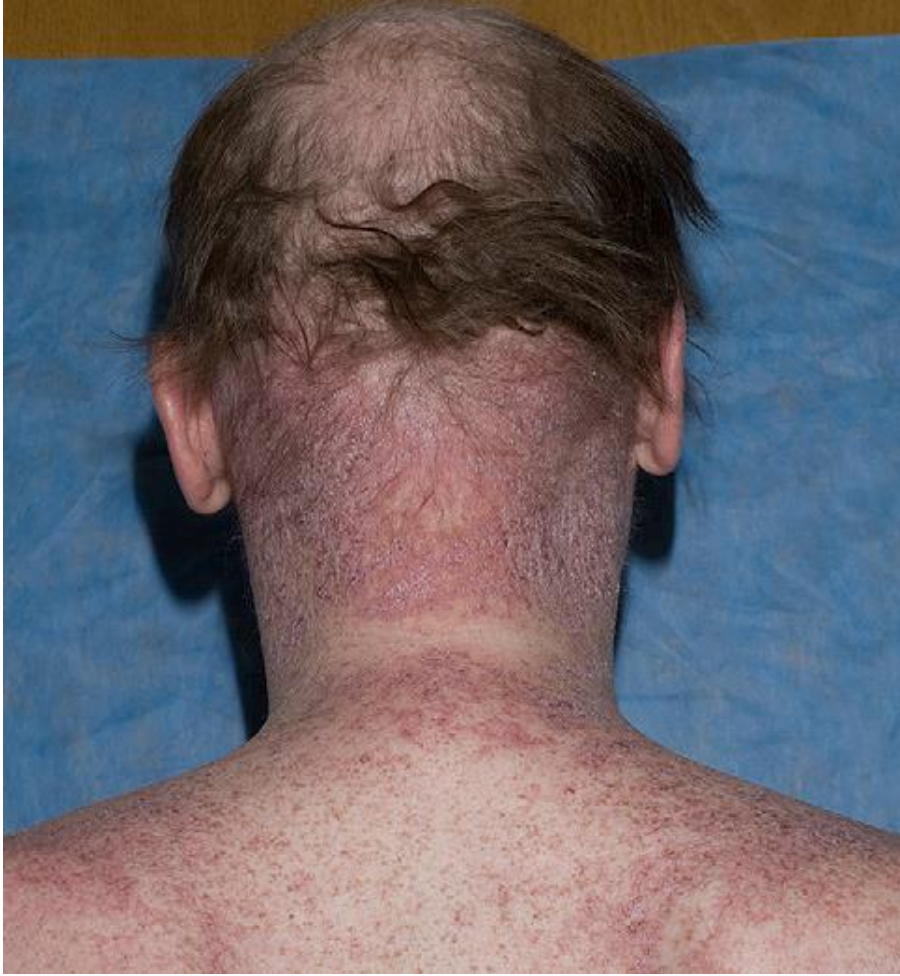
# There Are Two Presentations of Skin GVHD





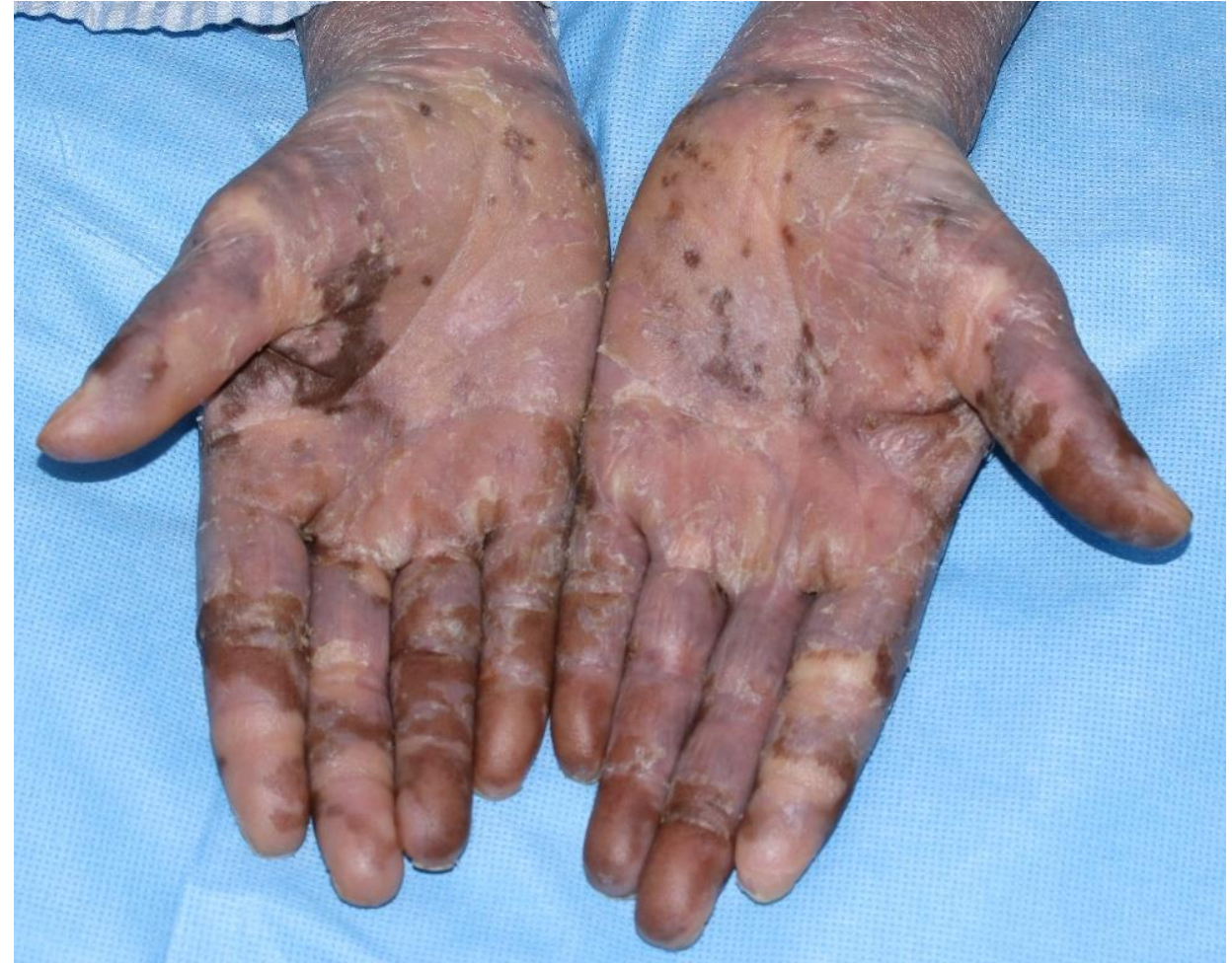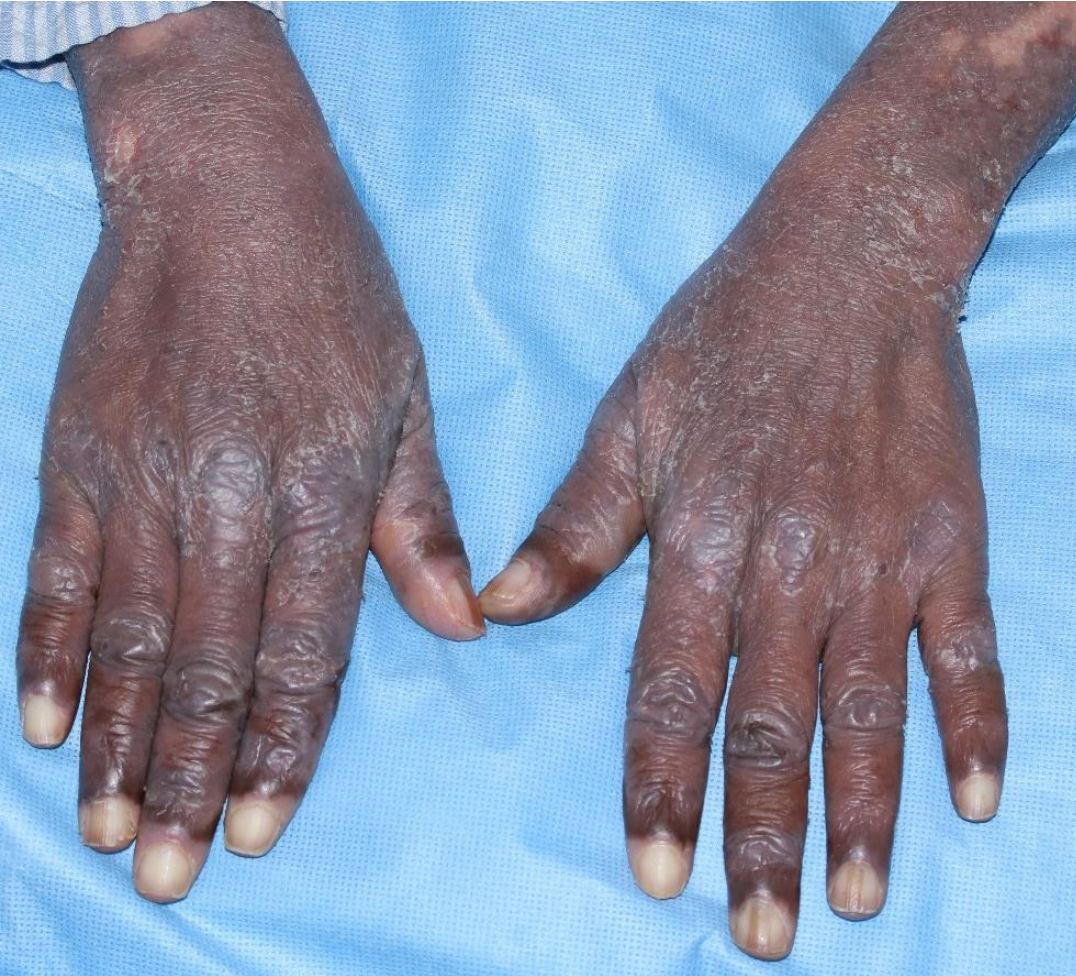# Non-Scarring (Non-Sclerotic) Lichenoid Chronic GVHD



J Am Acad Dermatol 2012;66:515.e1-18

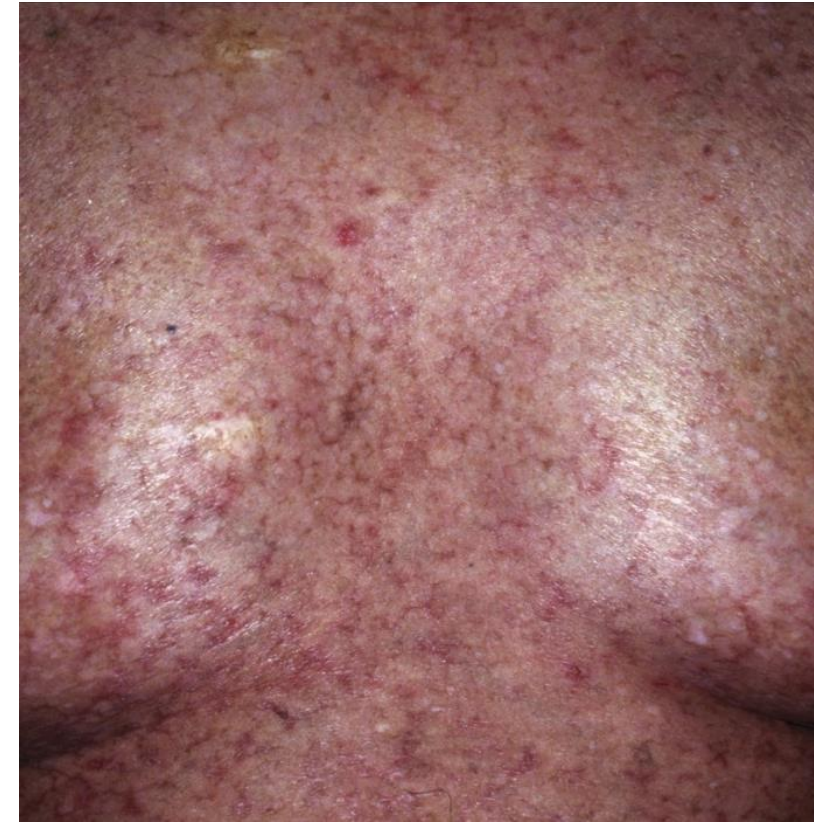
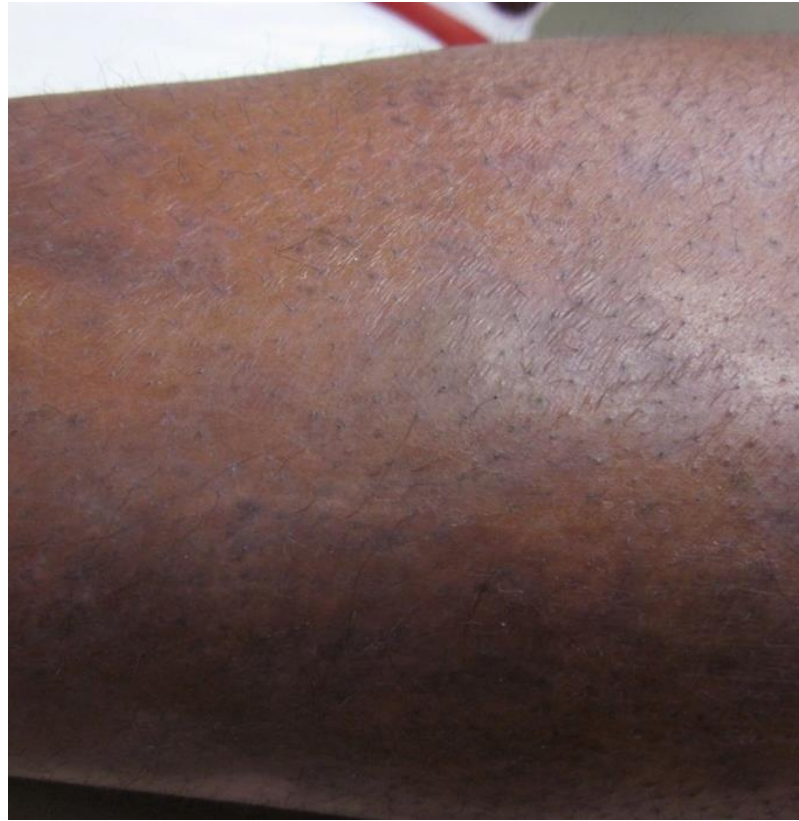
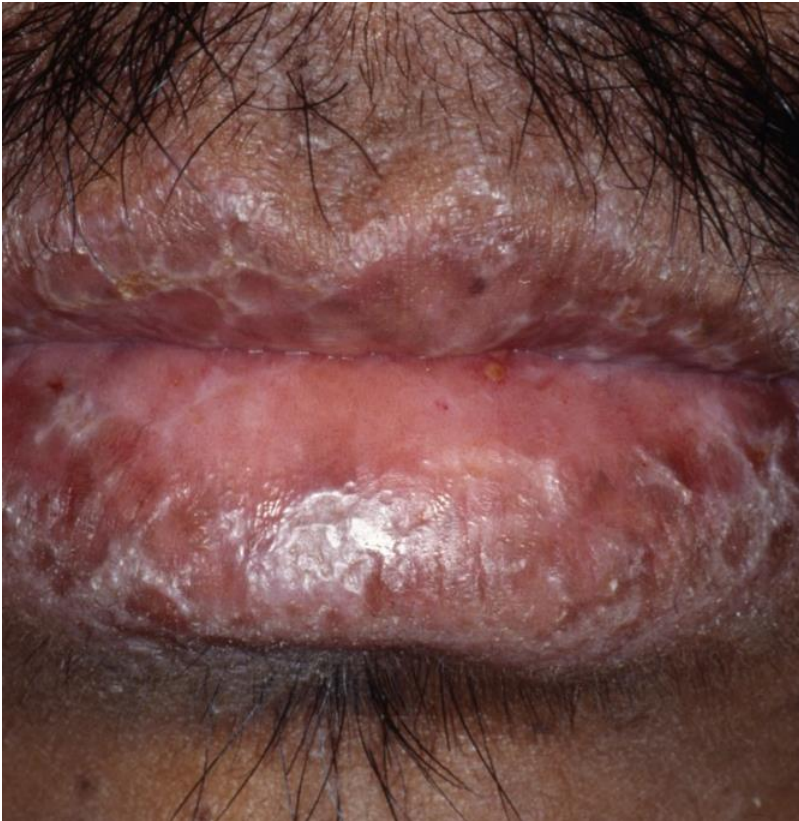
# Lichenoid Chronic GVHD May Be Extensive



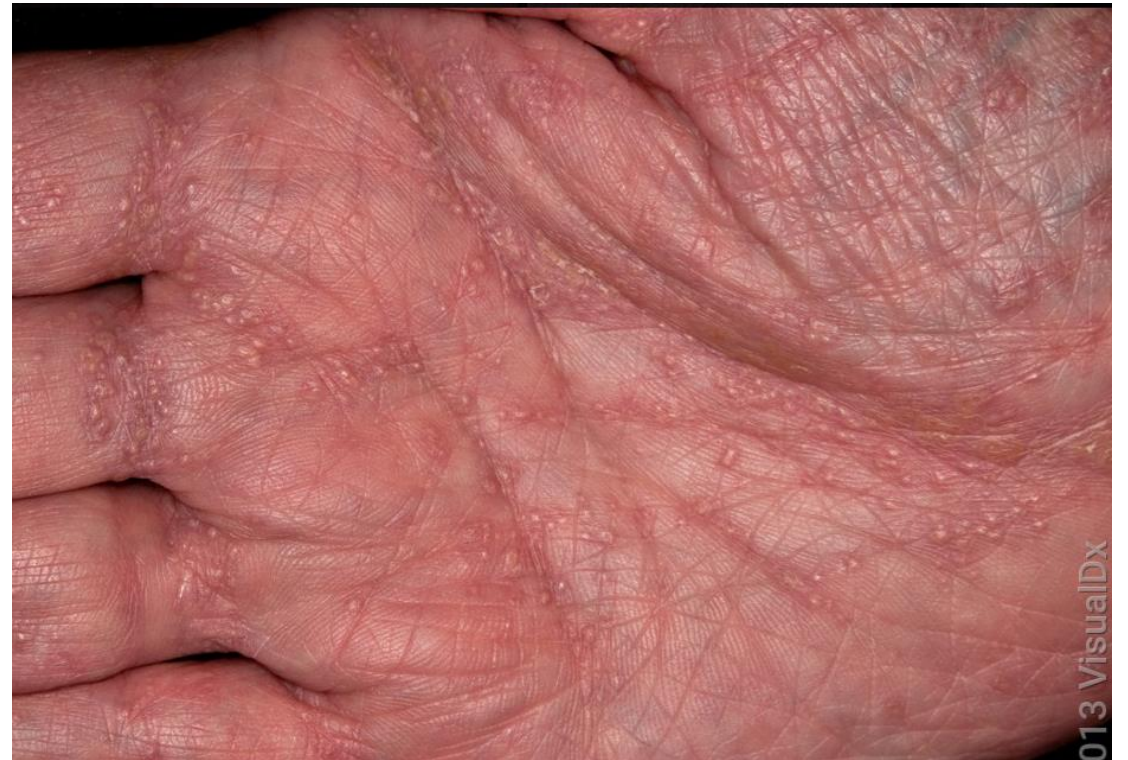
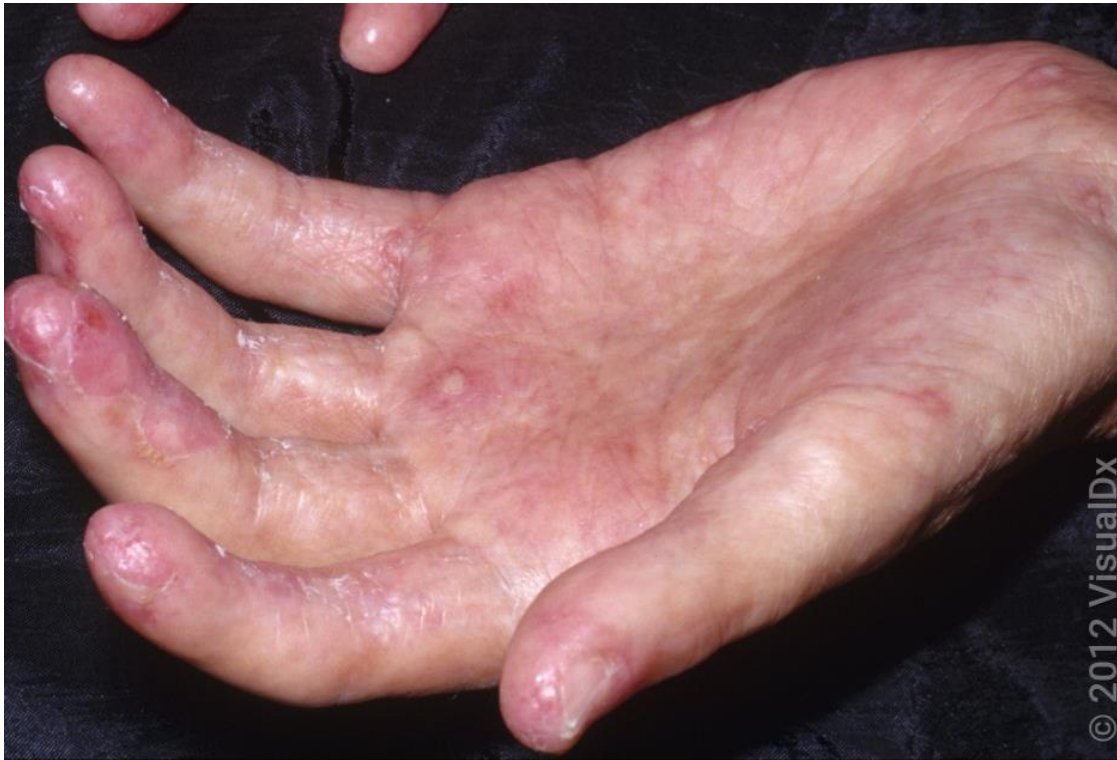
# Chronic GVHD of the Skin: Lichen Planus-Like





# Chronic GVHD of the Skin: Lichen planus-like



# Topical Therapies for Chronic Non-Scarring Skin GVHD

Localized

- Topical steroids
- Topical calcineurin inhibitors

Generalized

- NBUVB Phototherapy



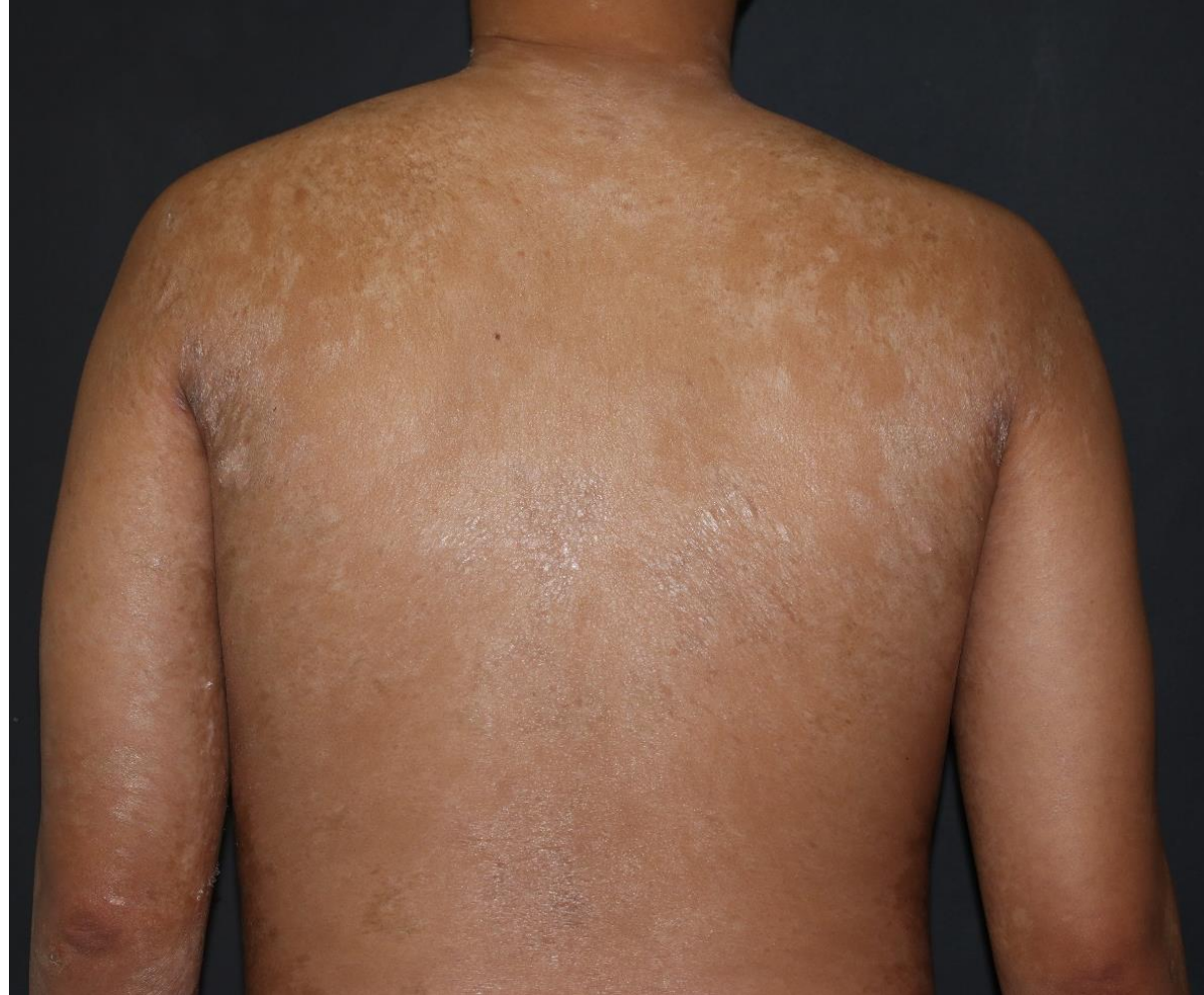

## GVHD of the Skin: Sclerotic GVHD

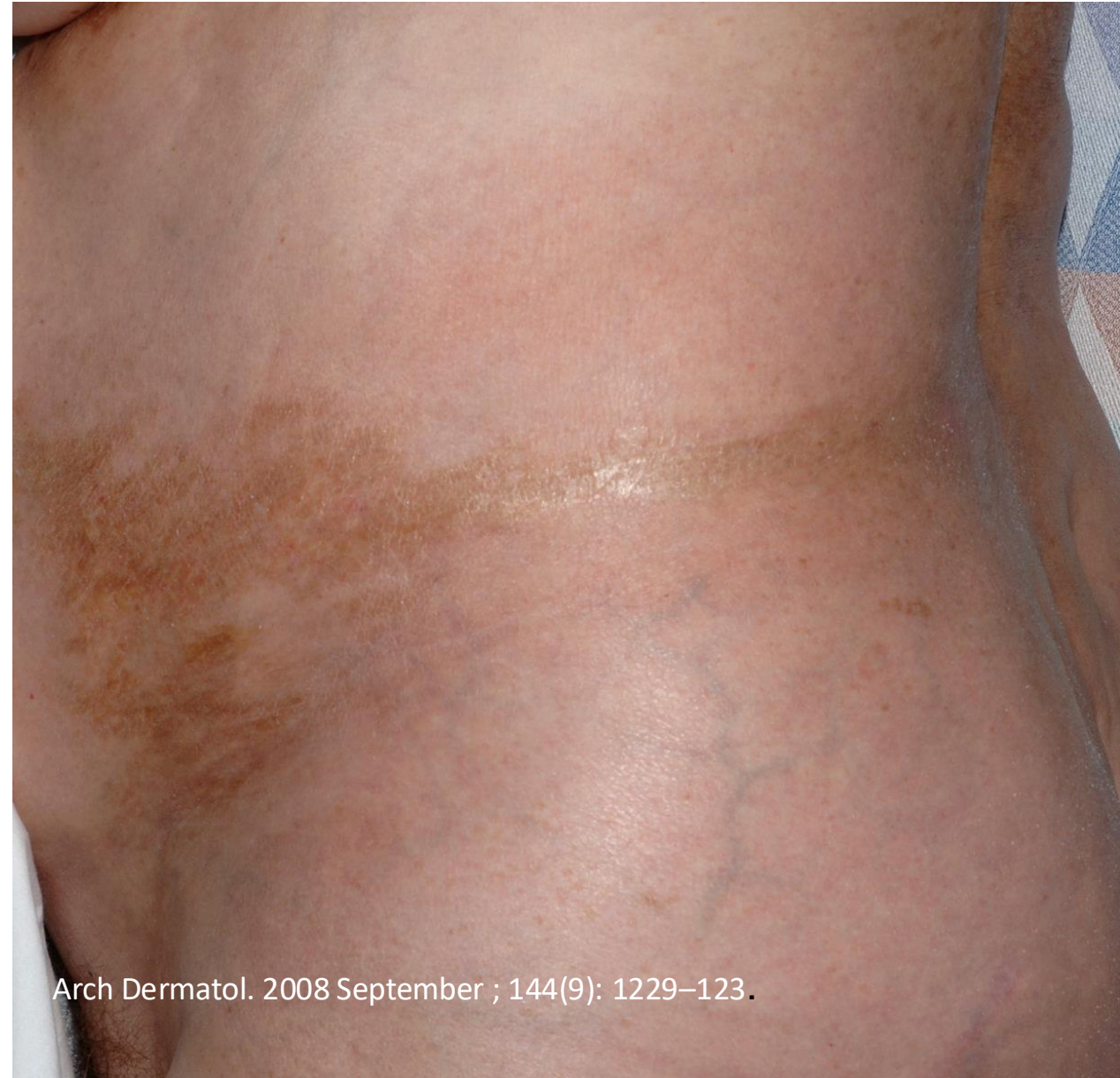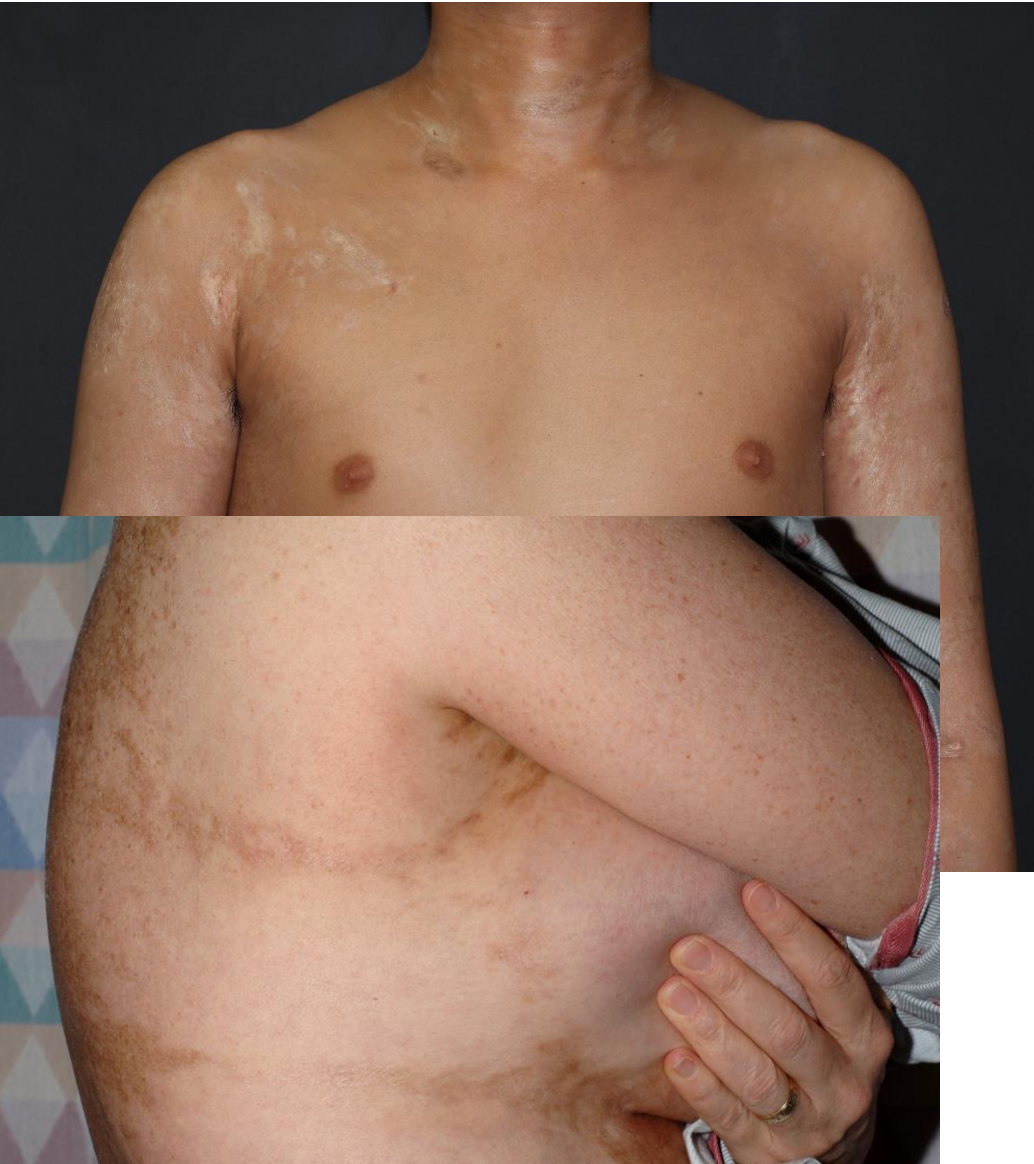




# Sclerotic GVHD



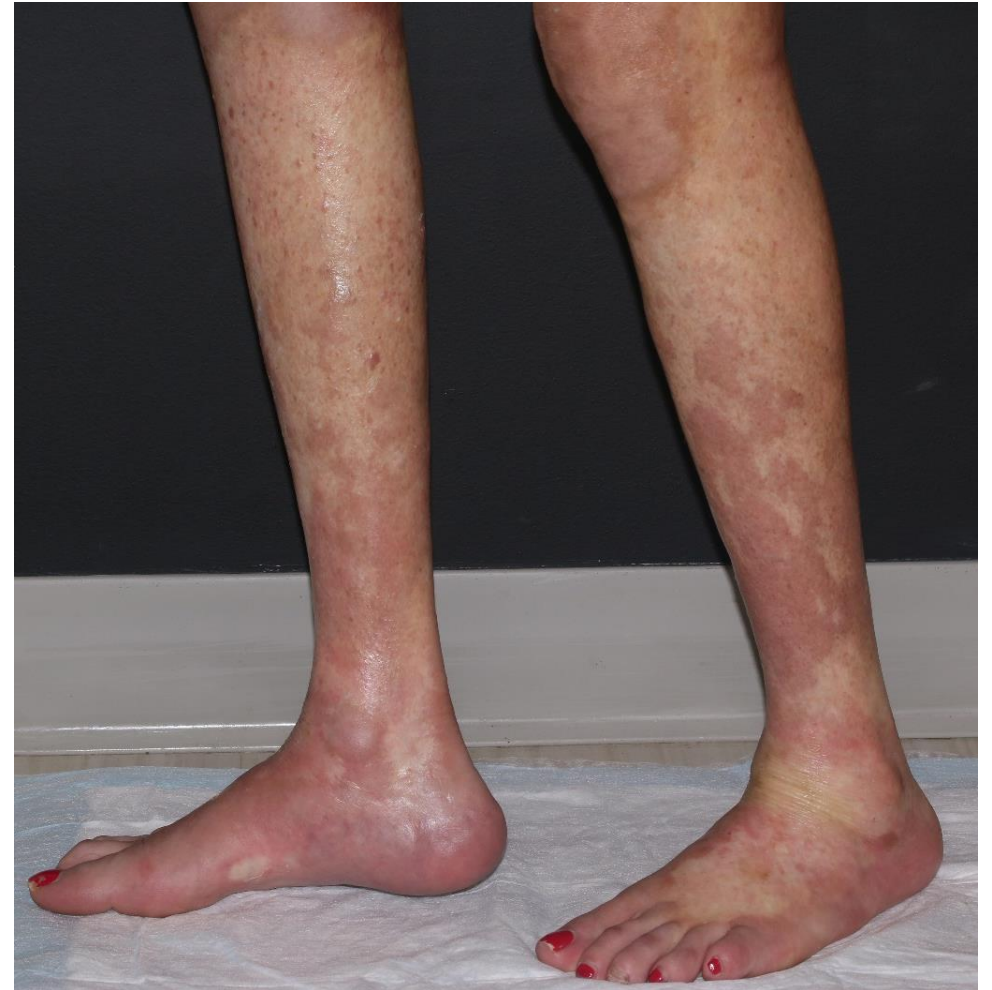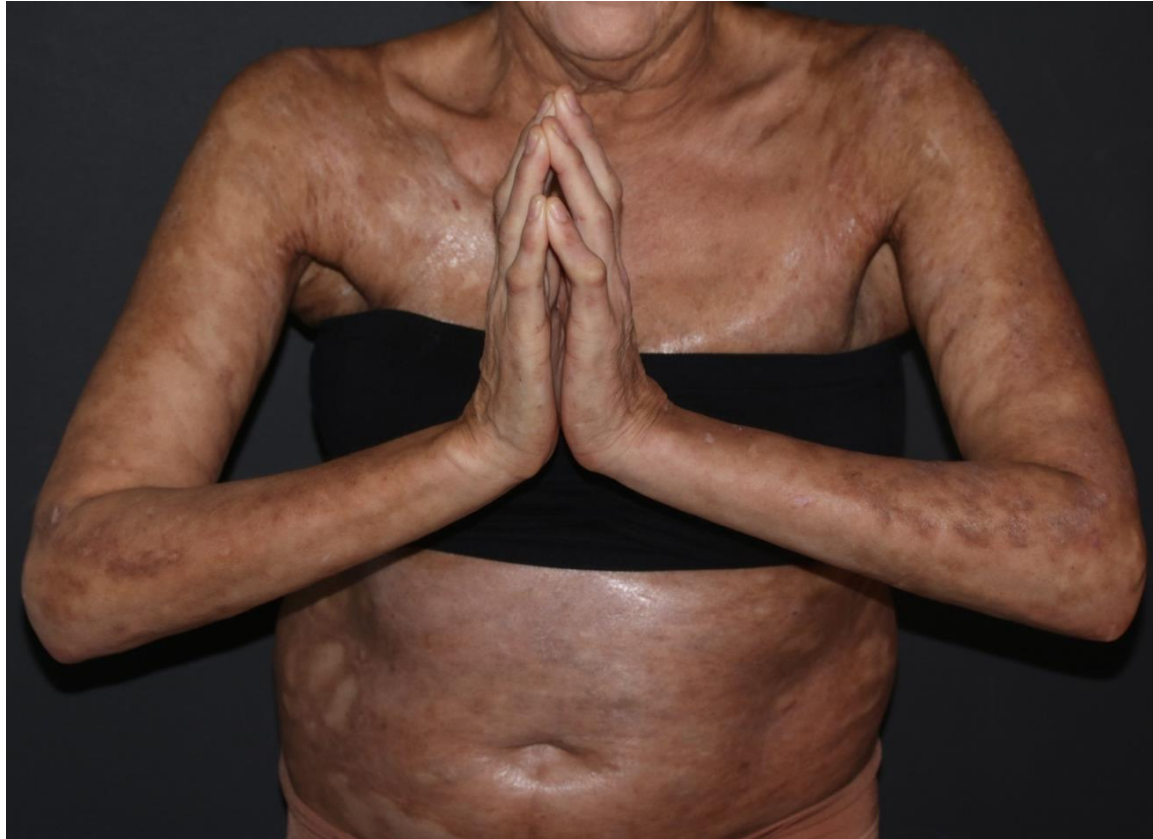# Sclerotic GVHD May Appear in Areas of Prior Trauma



Arch Dermatol. 2008 September ; 144(9): 1229–123.

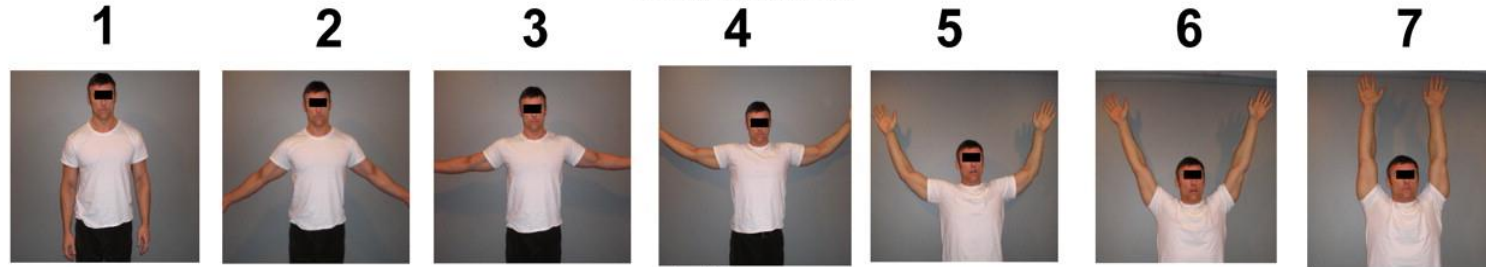

# Sclerotic Chronic GVHD May Lead to Reduced Range of Motion

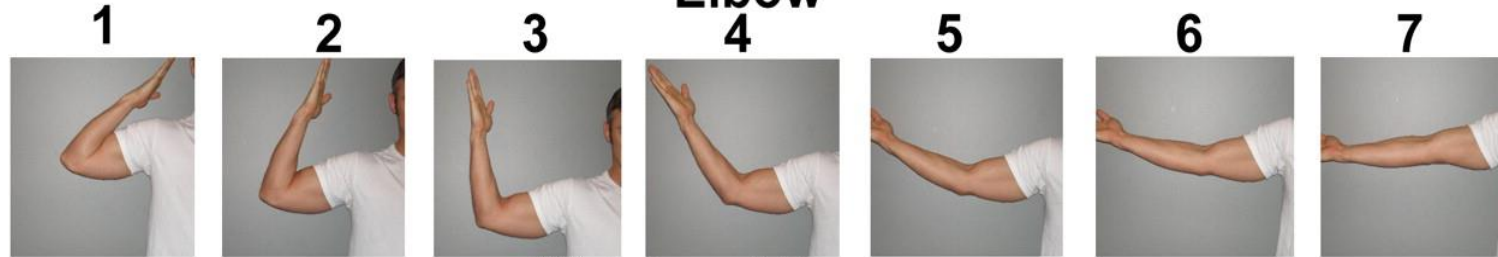


# Photographic Range of Motion (P-ROM)

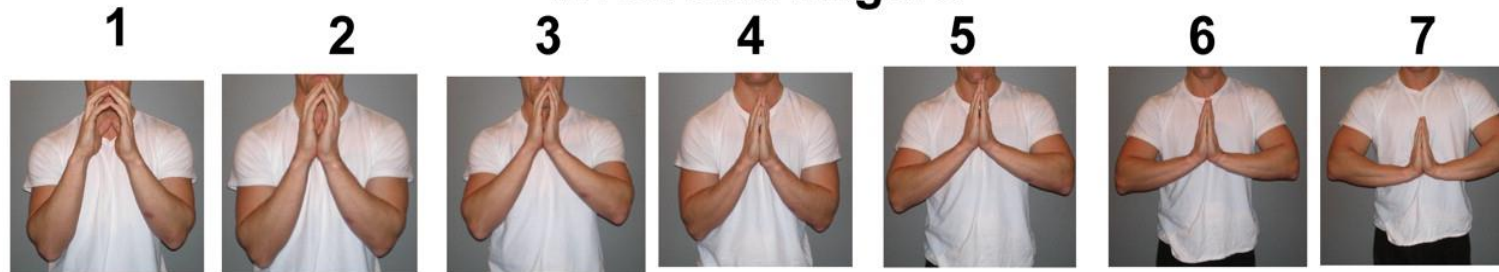## Shoulder



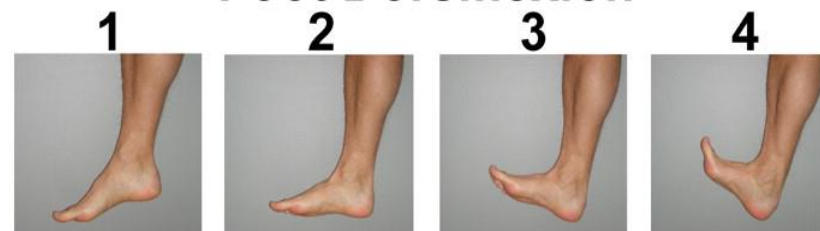## Elbow



## Wrist and fingers



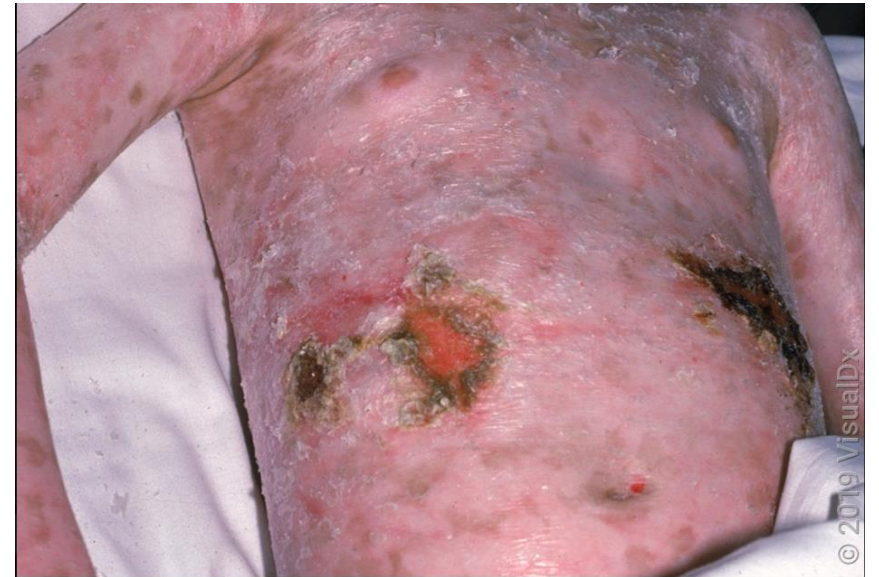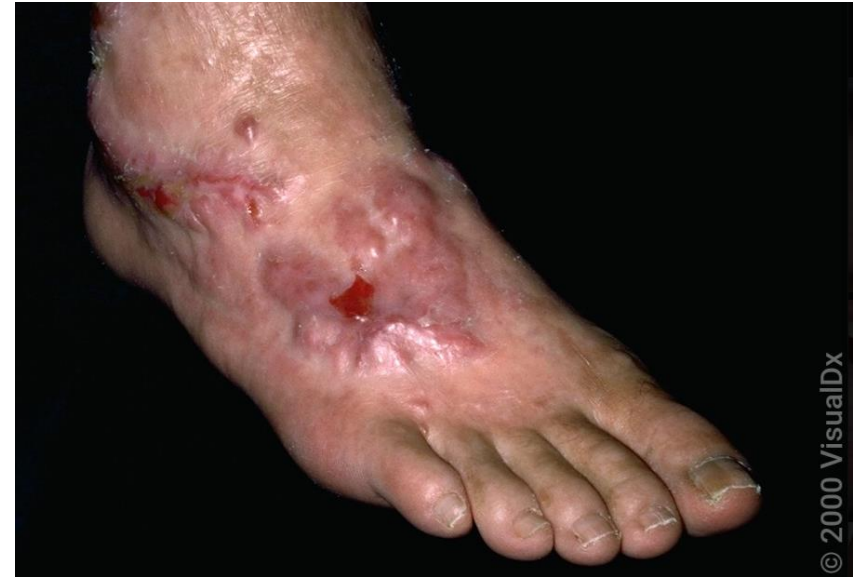## Foot Dorsiflexion



*National Institutes of  
Health Chronic Graft-  
versus-Host Disease  
Consensus for Clinical  
Trials: I. The 2014  
Diagnosis and Staging  
Working Group Report*



# Wounds May Develop Within Sclerotic GVHD



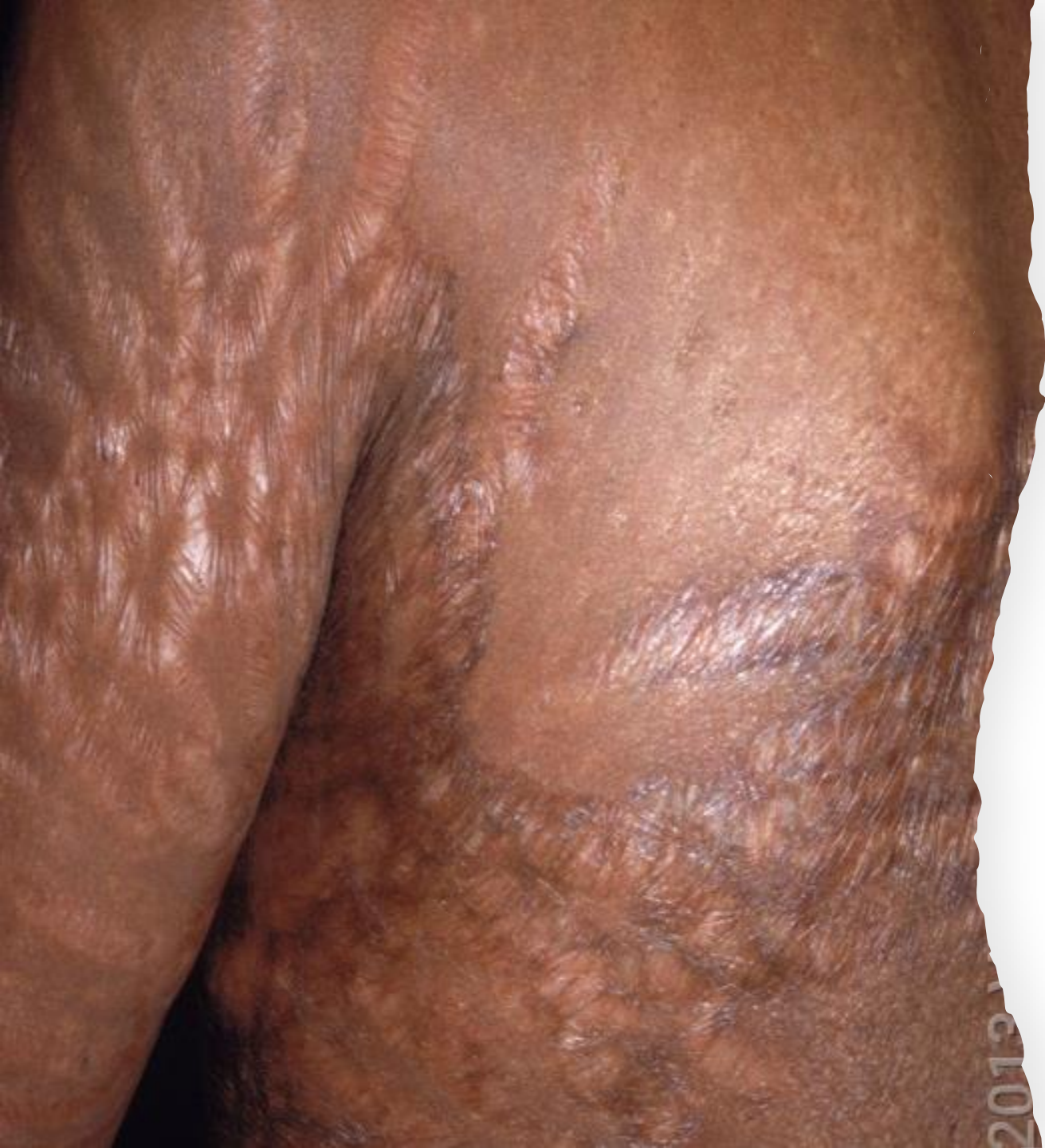# Topical Therapies for Chronic Scarring Skin GVHD

## Localized

- Systemic therapy as per BMT
- Minimally effective
  - Topical steroids
  - Topical calcineurin inhibitors
- Wound care

## Generalized

- Systemic therapy as per BMT
- UVA1 Phototherapy



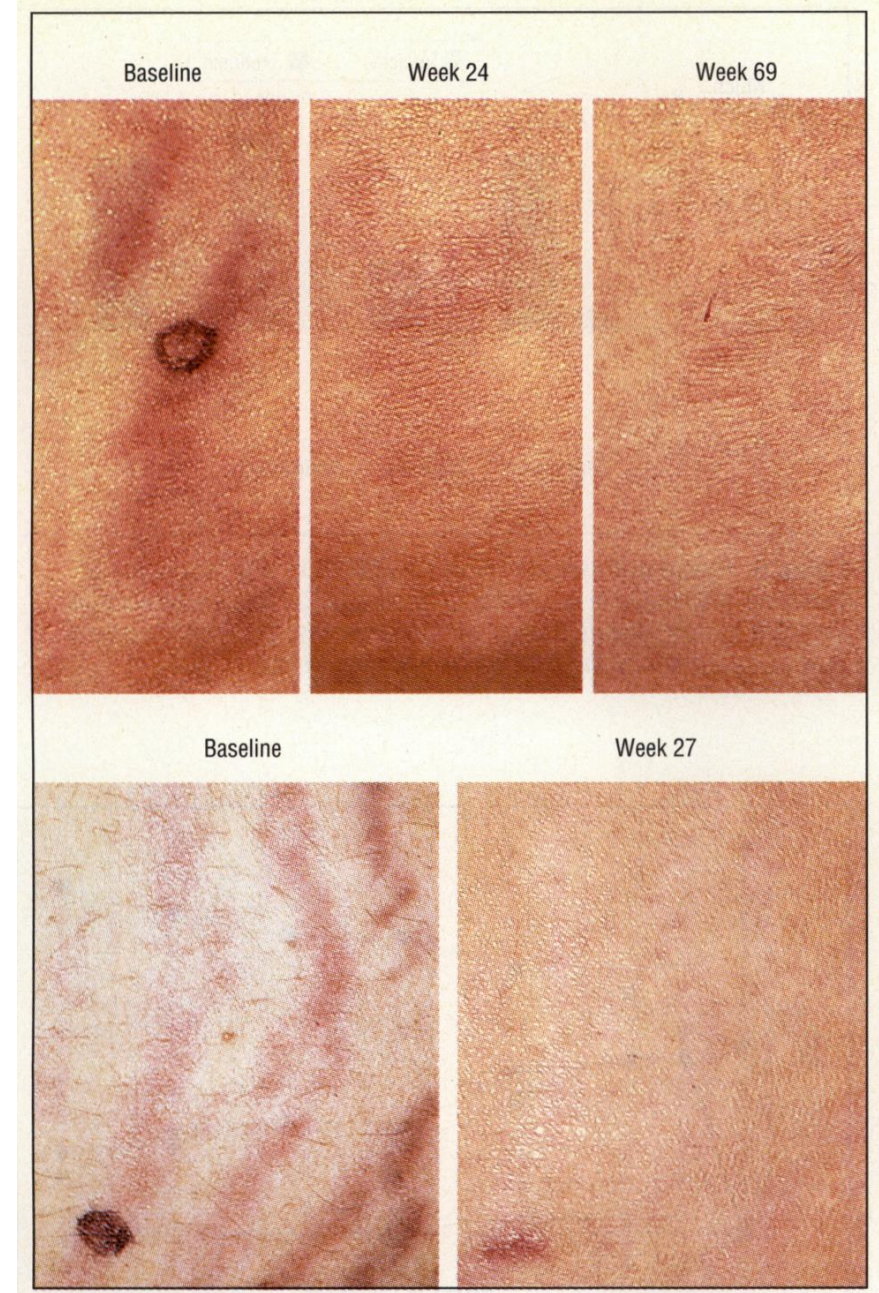
2013



# Stretchmarks: How to Treat

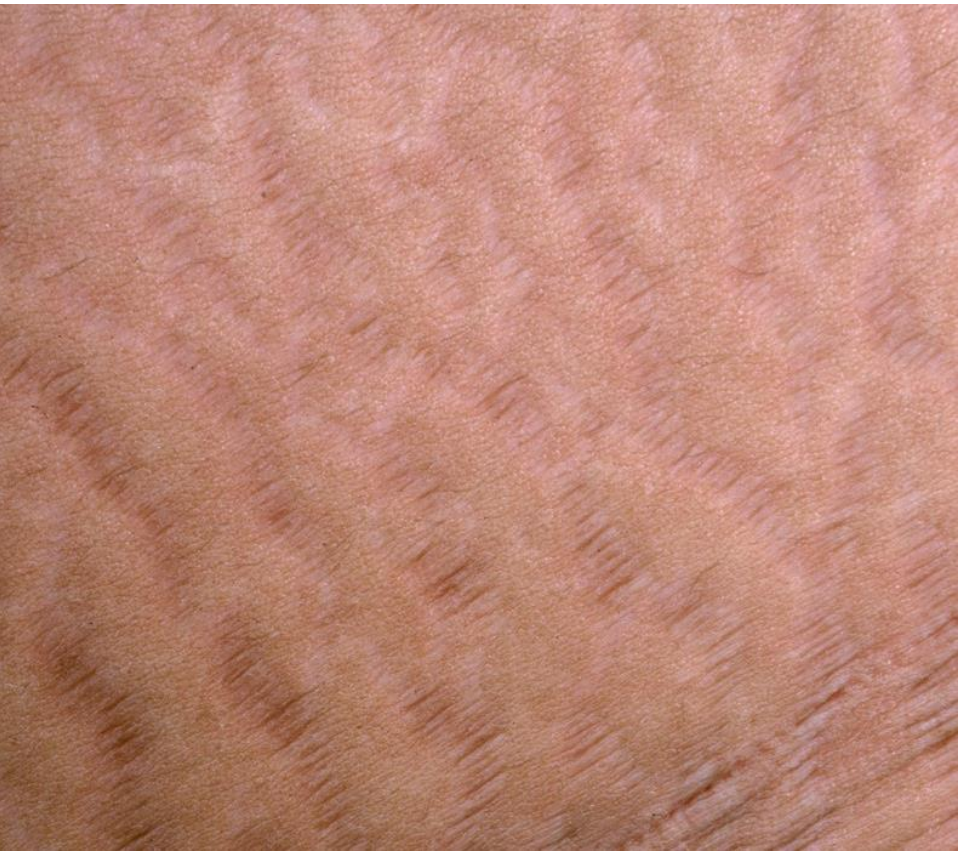
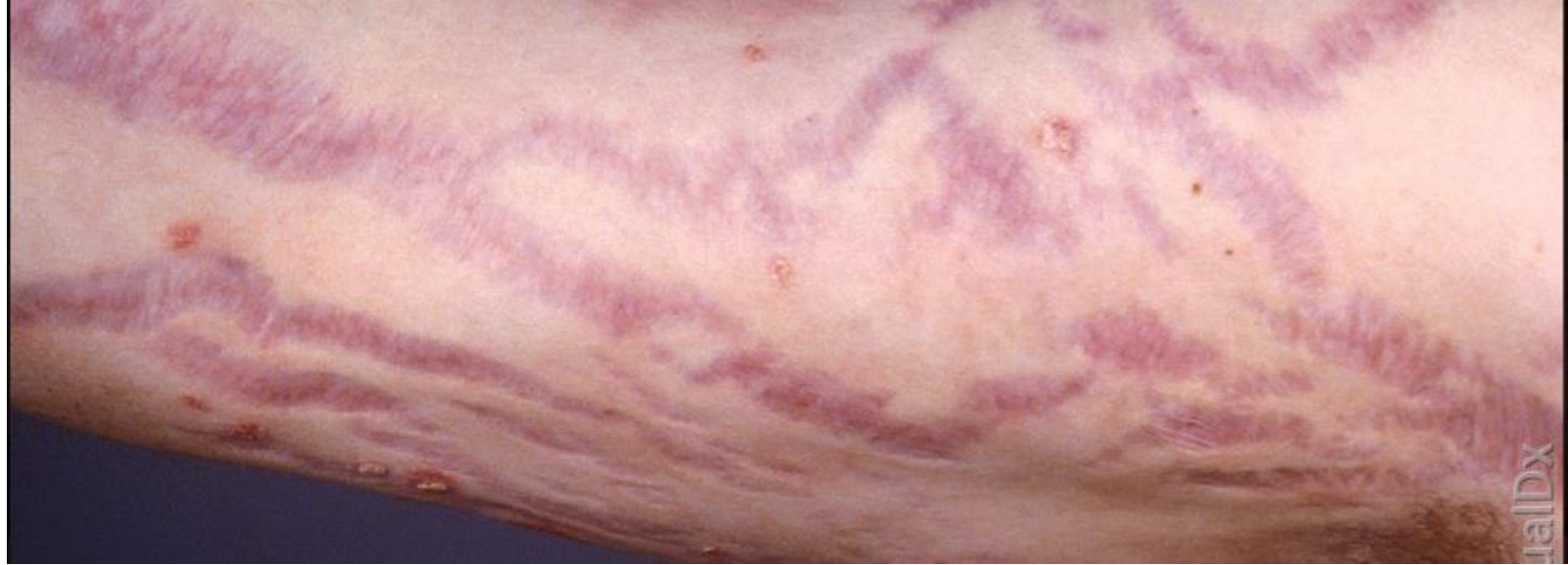
- Topical tretinoin improves early stretch marks
  - Reduces the length and width of stretch marks
- May experience dryness, erythema (pinkness), skin peeling with treatment

Kang S. *Arch Dermatol.* 1996;132(5):519–526.






Stretchmarks may  
be treated with  
laser

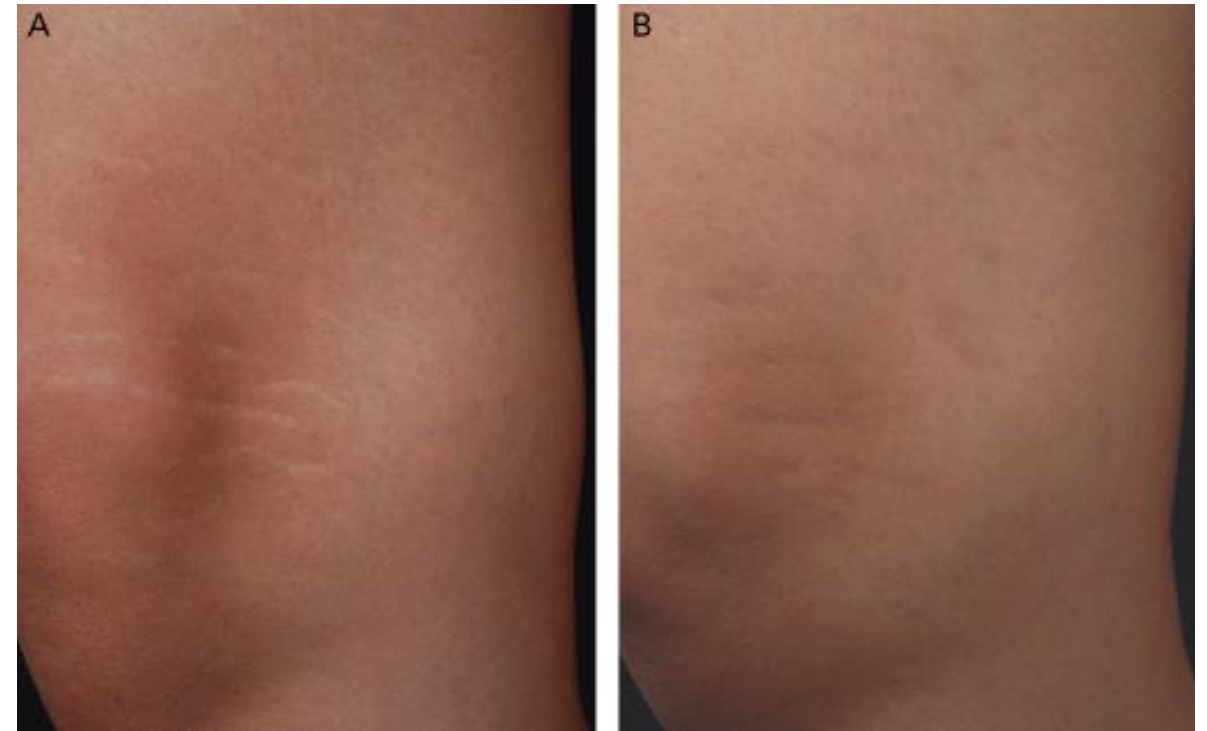
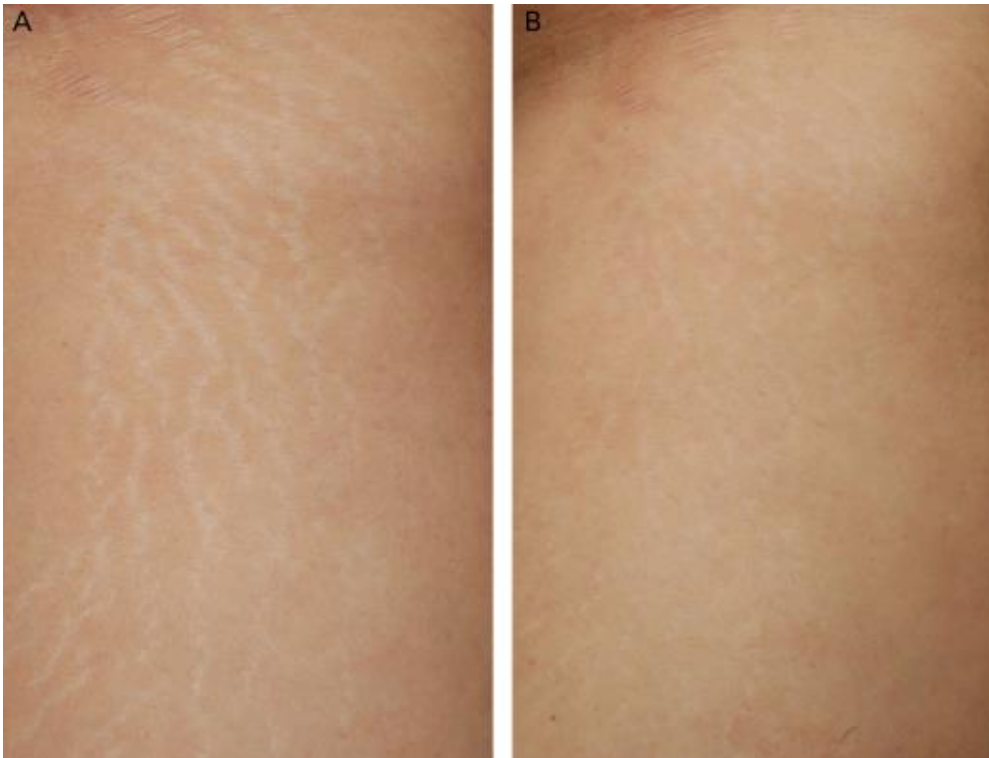

Thin texture →  
Laser (e.g.  
fractional CO2  
or Er:YAG  
laser)



Pink →  
Laser (e.g.  
pulsed dye  
laser)

# CO2 Laser May Have a Positive Effect on Late-Stage Stretch Marks

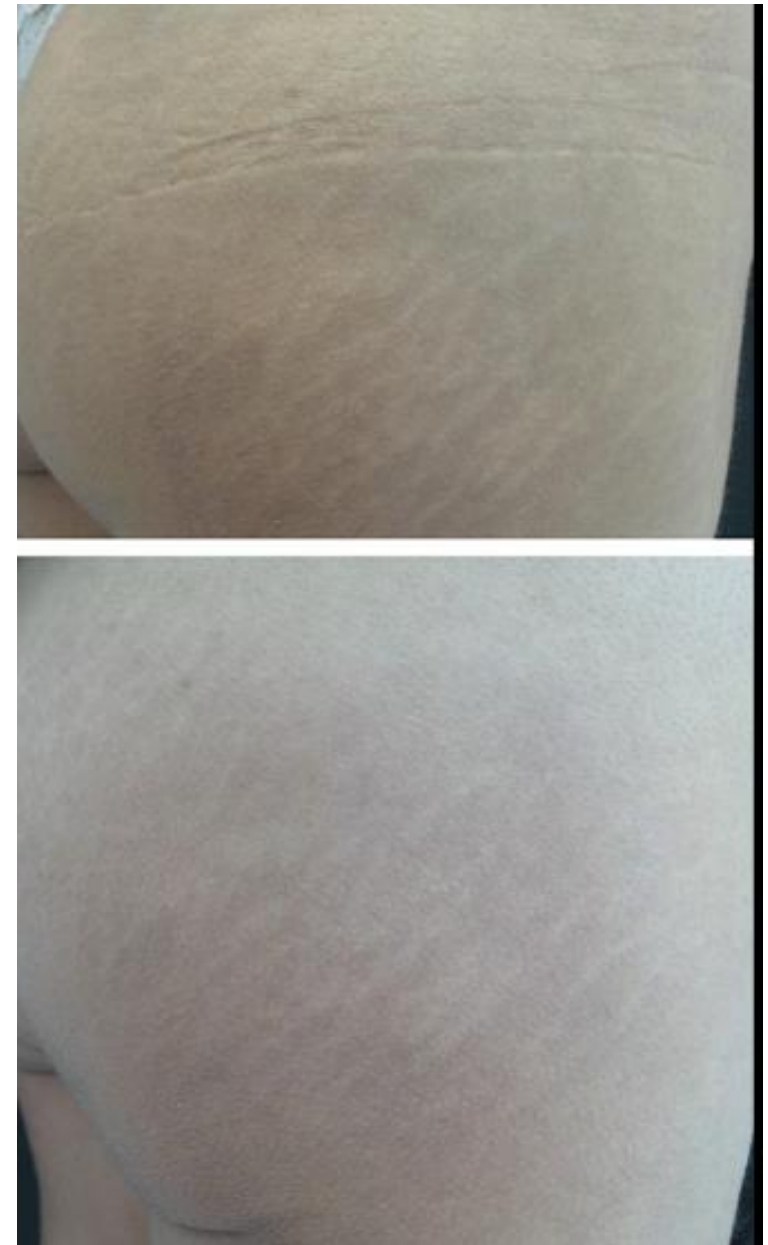

Lee SE. *Dermatologic Surgery*. 2010; 36 (11): 1683-1690.

# Microneedling May be a Safe and Effective Treatment for Stretch Marks

- Striae improved by >50% after ~2 treatments
- Main side effects are transient erythema (pinkness)

Dermatologic Surgery 46(4):459-464, April 2020.





# Cleansing When You Have Skin GVHD

## Handwashing

- Wash your hands to prevent infections
- Dry your hands with a clean towel but leave some water on your hands
- Fragrance-free moisturizer

## Showers

- <20 min bath/shower with lukewarm water
- Use gentle, fragrance-free, soap or cleanser (bar soaps)
- Avoid antibacterial soaps/cleansers (with triclosan)



# Order of Skin Products When You Have GVHD

1

+/- Medicated  
cream or  
ointment

2

Moisturizer

3

Sunscreen

4

+/- Makeup

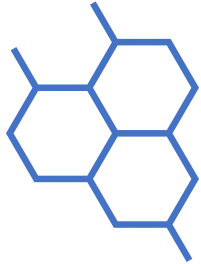


# Moisturizing When You Have Skin GVHD

Choose	Choose an ointment or cream
Apply	Apply petroleum jelly or moisturizer your care team recommends when skin is still damp
Seal	Cover moisturized hands/feet with cotton gloves or socks to seal in the moisture.



# Choosing a Sunblock When You Have Skin GVHD: Two Categories of Sunscreens




**Chemical: octinoxate, oxybenzone, avobenzone**

Easier to spread on skin

Available in water-resistant options

May be best if you do not have sensitive skin



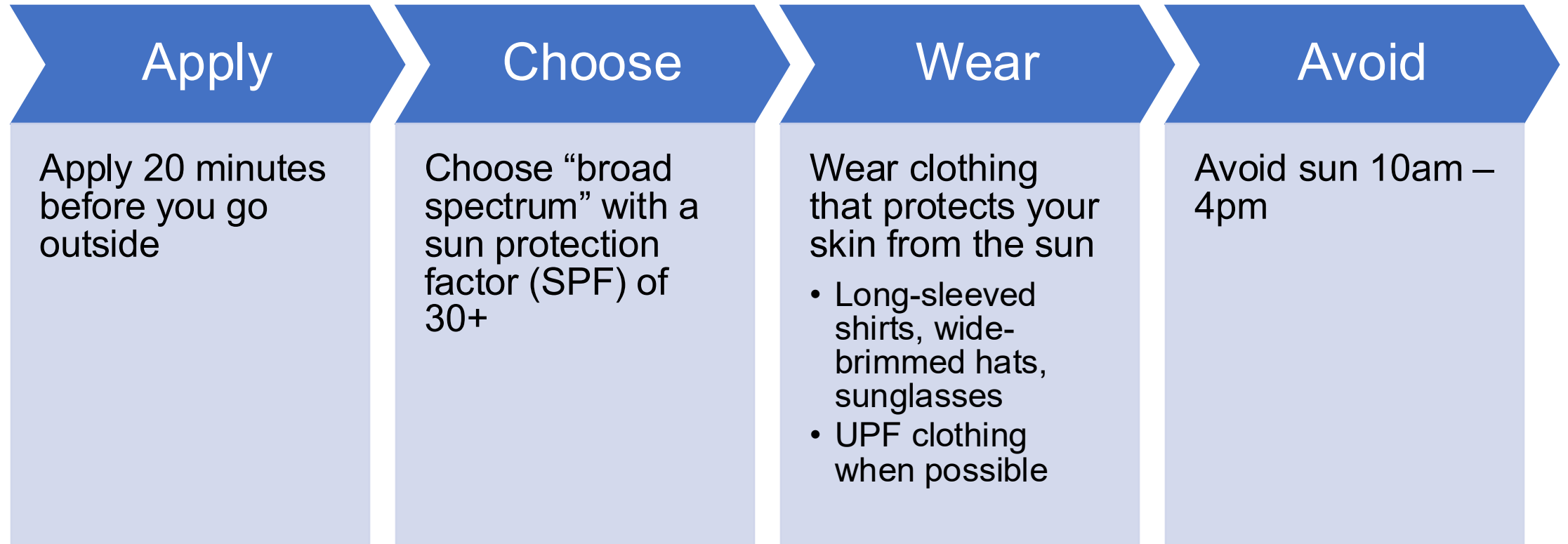
**Mineral: zinc oxide, titanium dioxide**

Thicker, may not rub into skin as easily

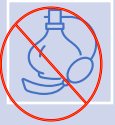Better choice for sensitive skin



# How to Sun-Protect When You Have GVHD



# Using Makeup When You Have Skin GVHD



Choose fragrance-free products made for sensitive skin



Avoid products that are natural or unpreserved: they may have germs



Try one product at a time every few days. You may have new allergies even to products you previously used.



OK to use makeup to cover a rash if the skin is not broken, and concealer to cover dark or light spots

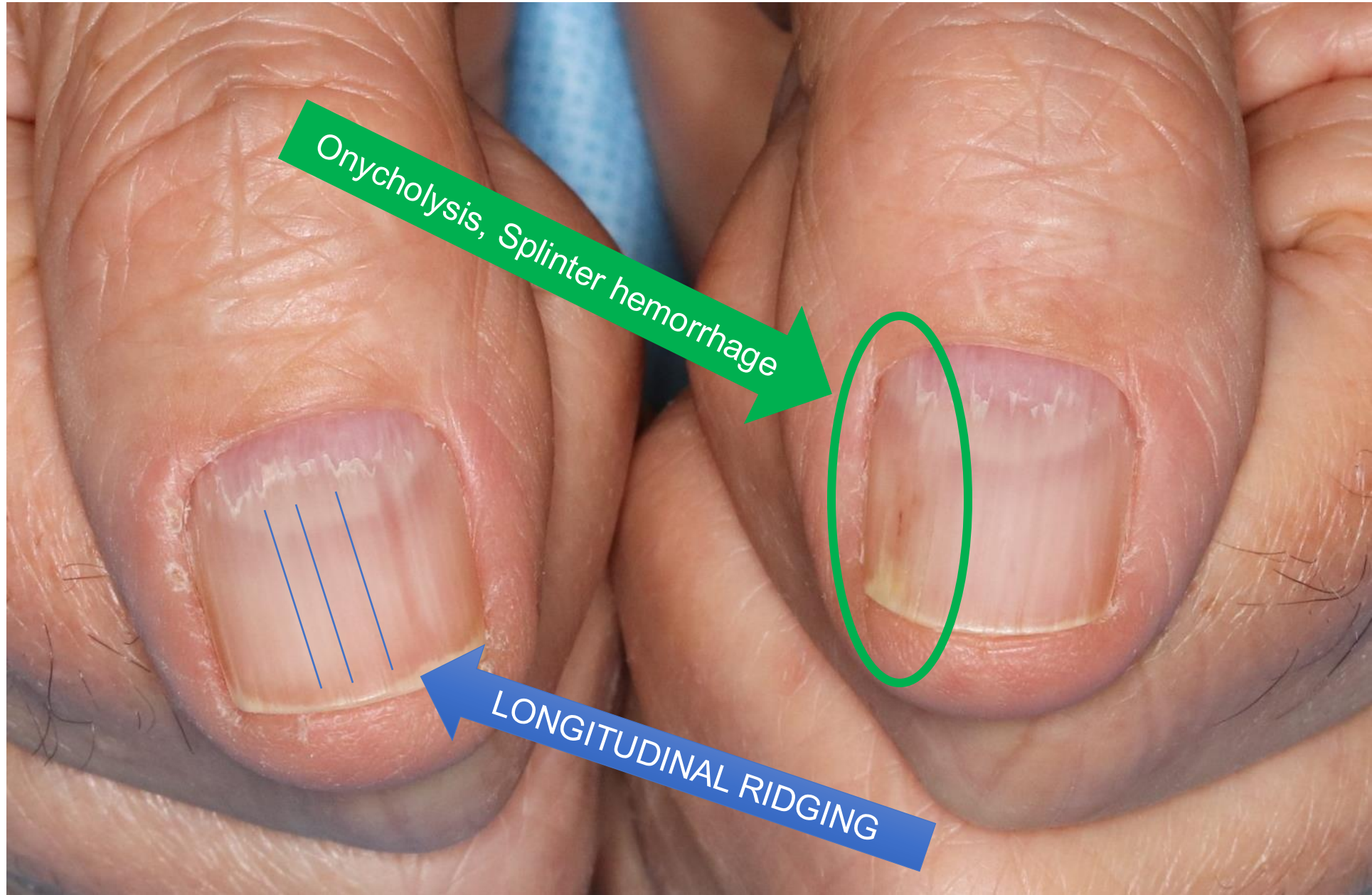


# Replace Makeup Products When You Have Skin GVHD

- Throw out your older products and buy new ones regularly
- Replace mascaras every few months
- Replace eyeshadow every year
- Replace foundation every 1-2 years
- Replace lipsticks and blushes every 1-2 years

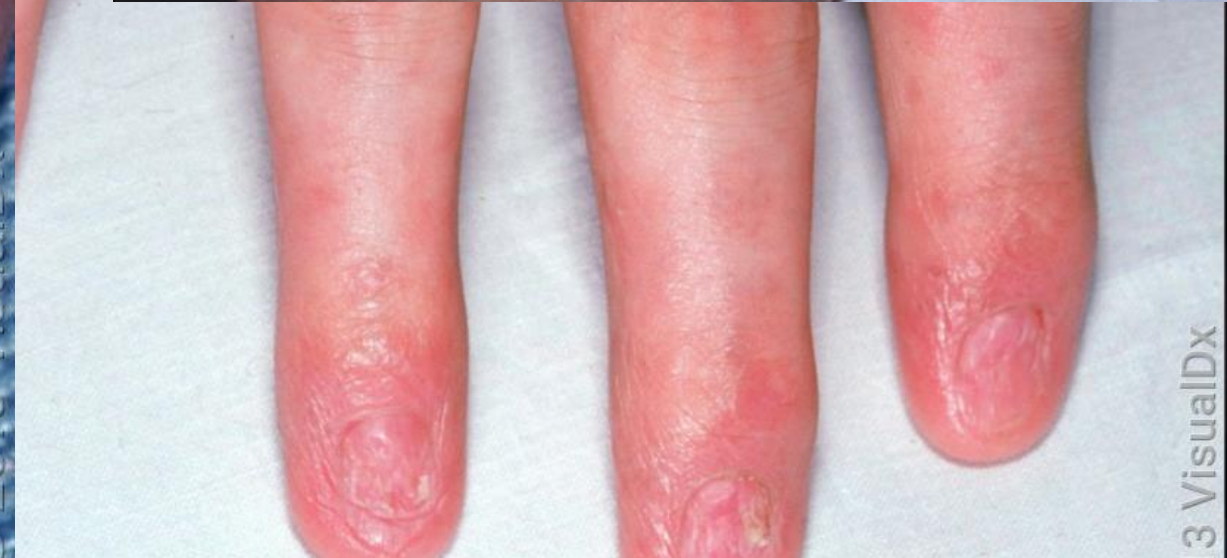
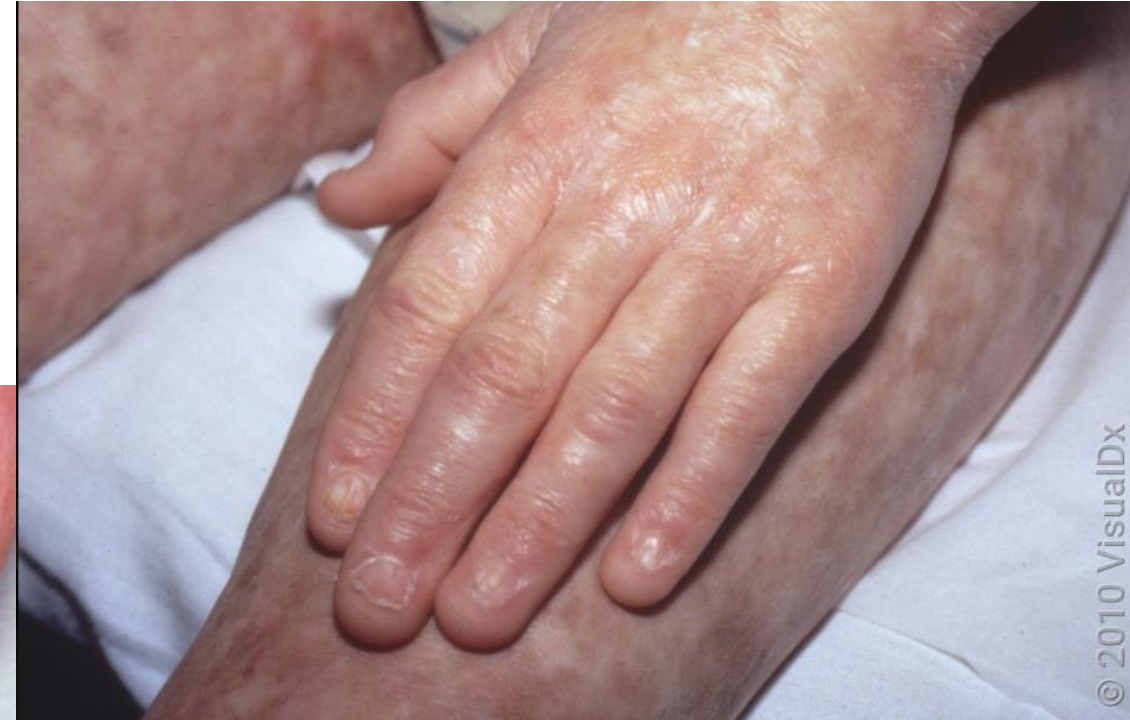
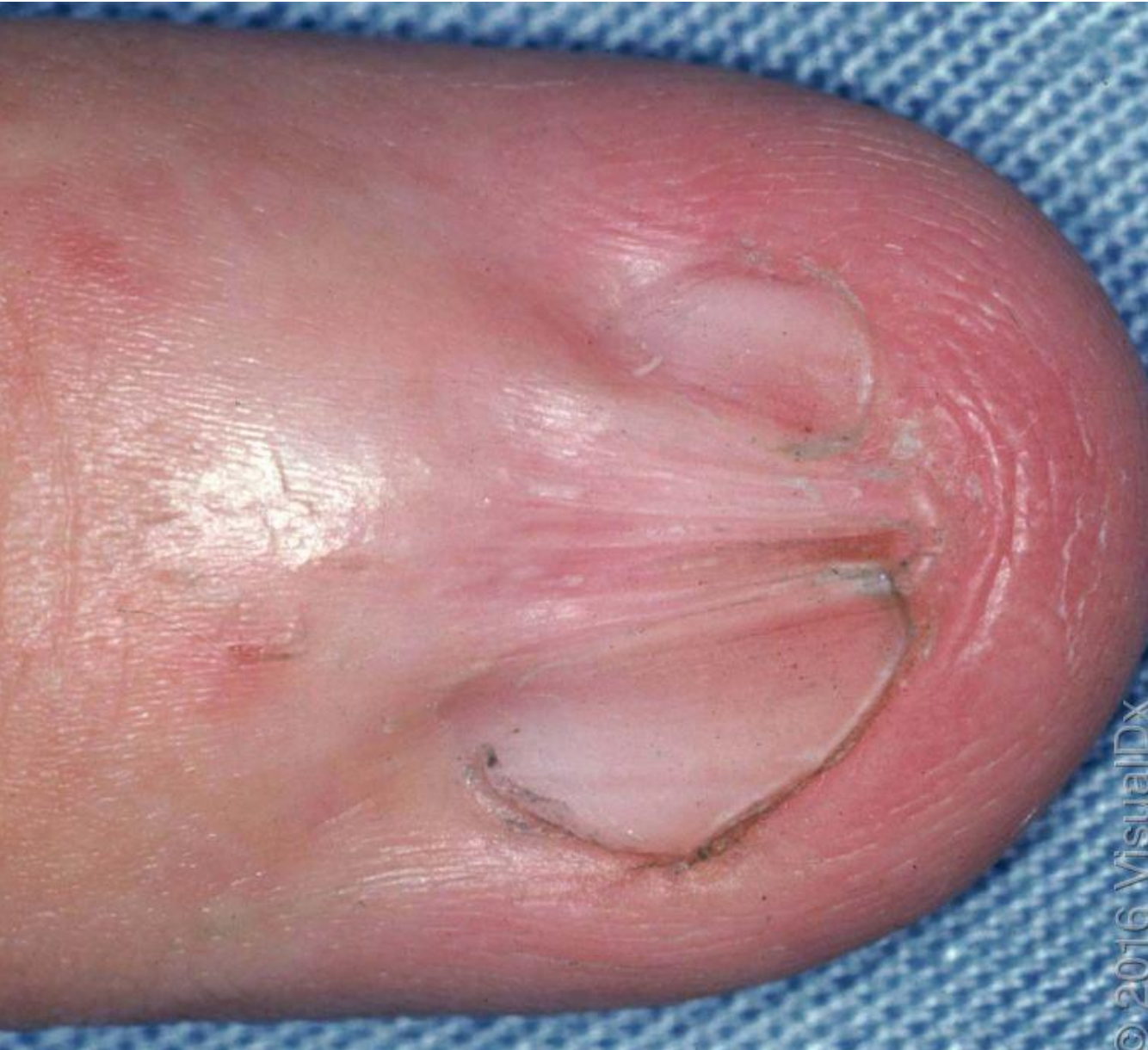# Nail Changes May Be Asymptomatic





# Patients May Experience Nail Loss



# Treatments for Nail Changes

## Brittle, Breaking, Lifting, Scarring

- Sally Hansen Hard as Nails™
- Nailtek™
- Oral biotin
- High potency topical steroid

## Scarring

- Steroid injection into nail fold
- Systemic therapy for GVHD



# Hair Loss after Transplant

Anagen effluvium = Hair loss in the first 6 months after chemotherapy

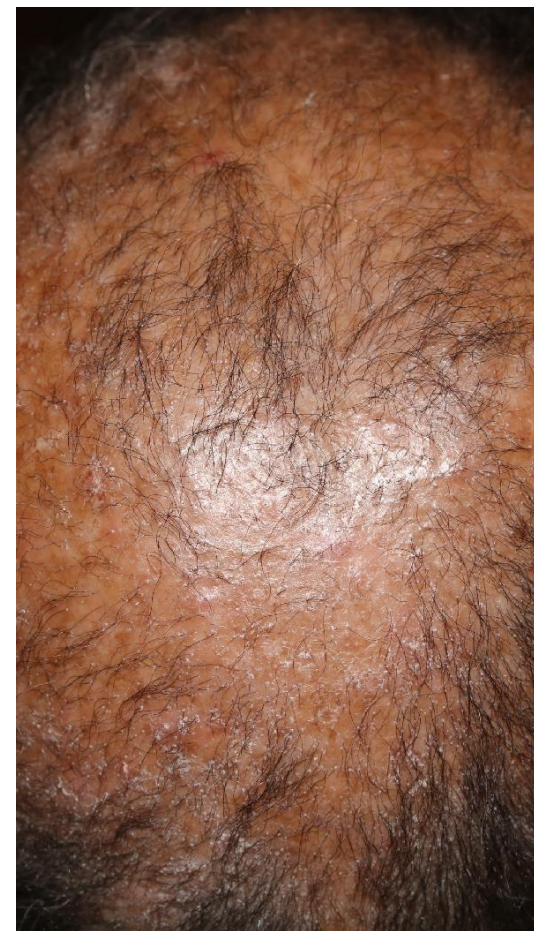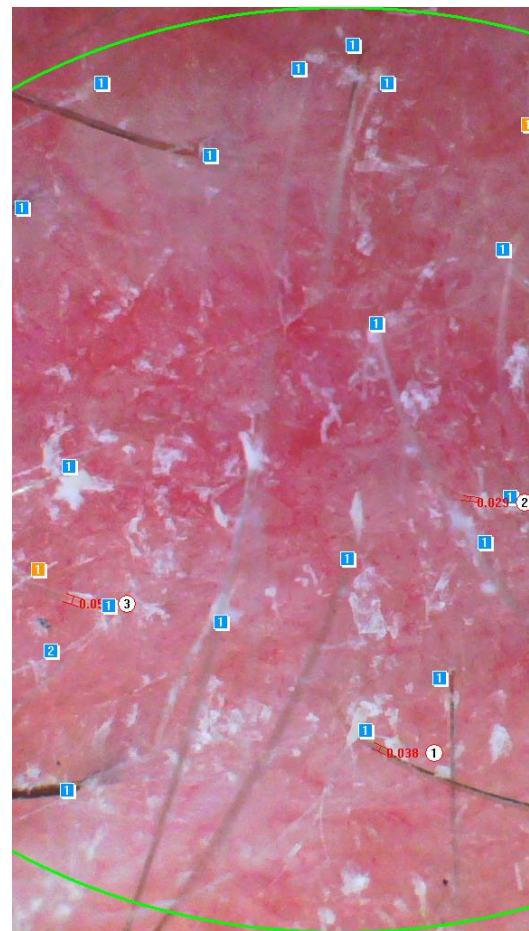
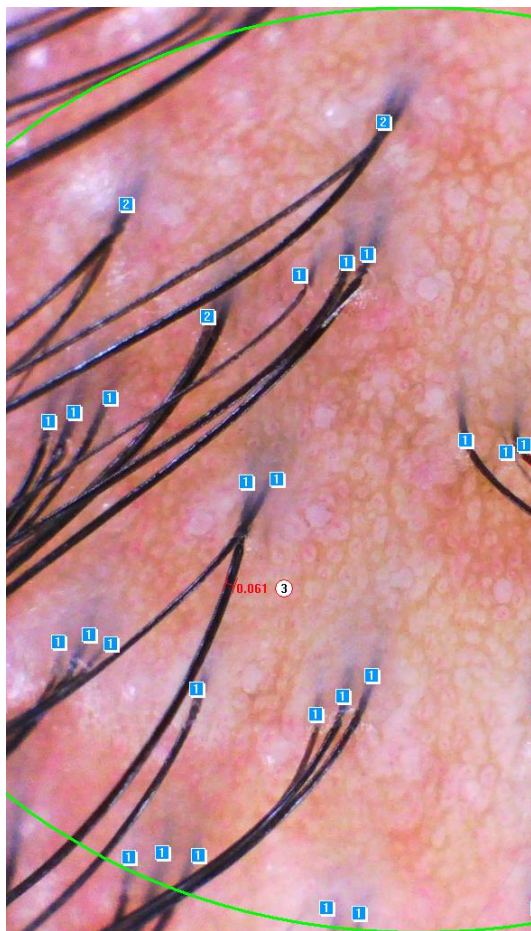

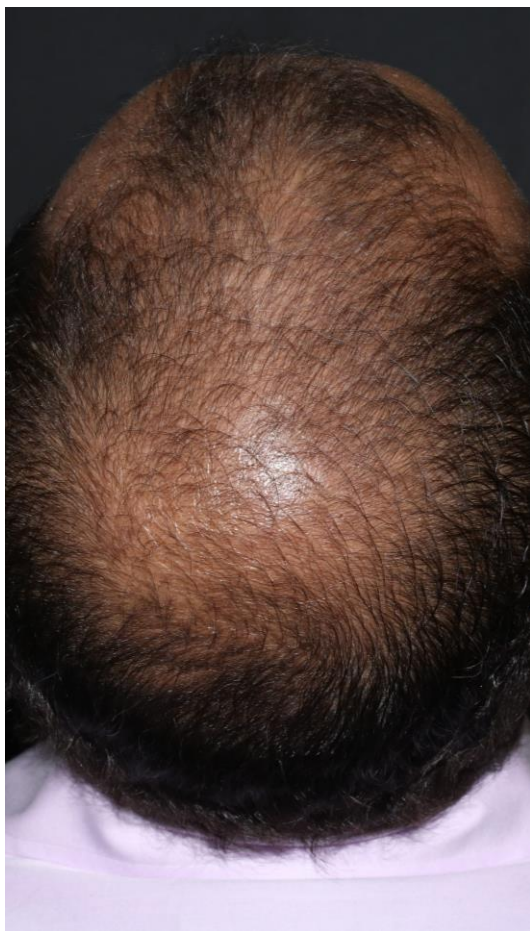
Persistent chemotherapy induced alopecia = hair loss lasting > 6 months after chemotherapy

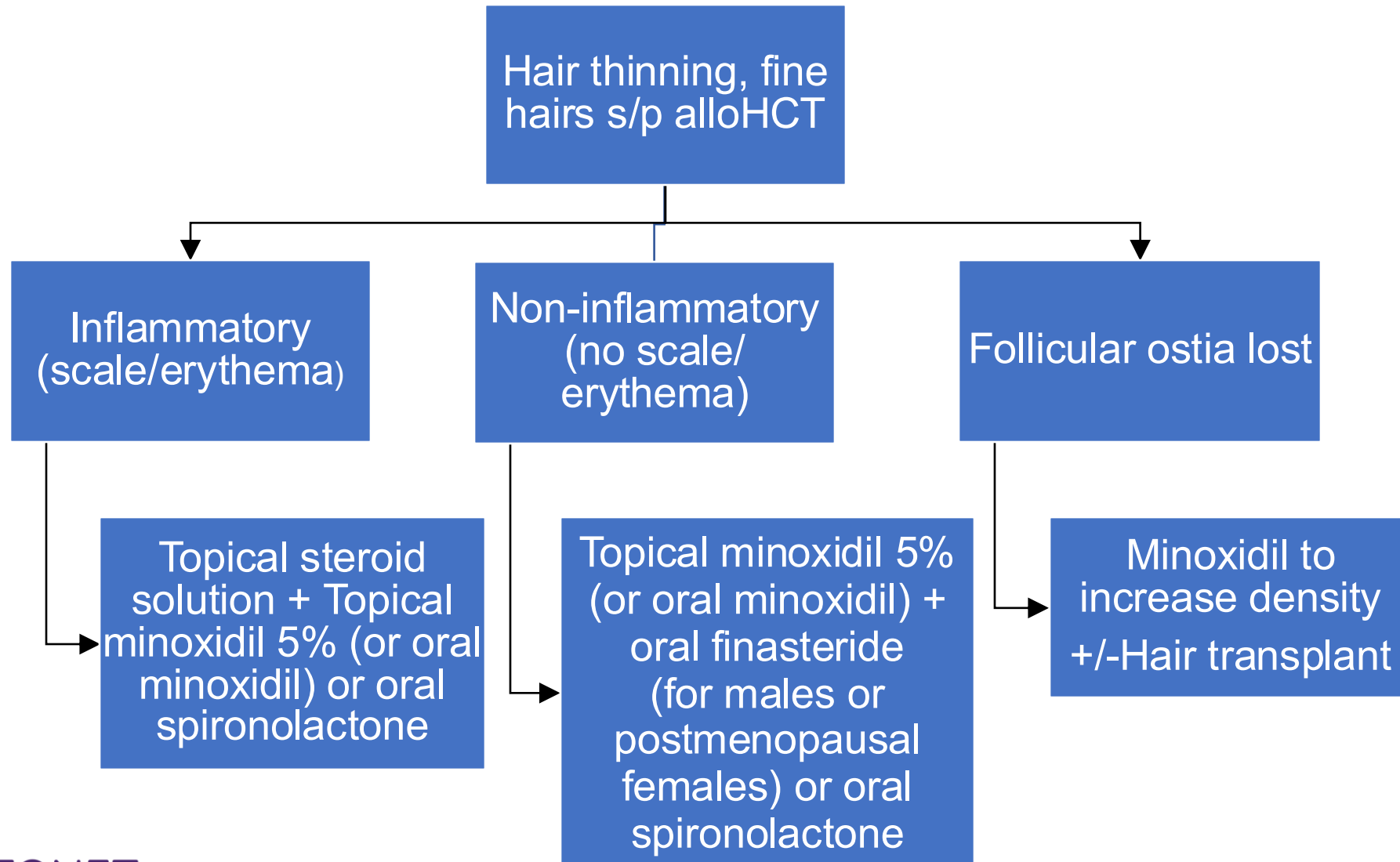
GVHD associated hair loss may occur as part of chronic GVHD



# GVHD Hair Loss May Be Scarring or Non-Scarring



# Topical Therapies for GVHD of Scalp/Hair

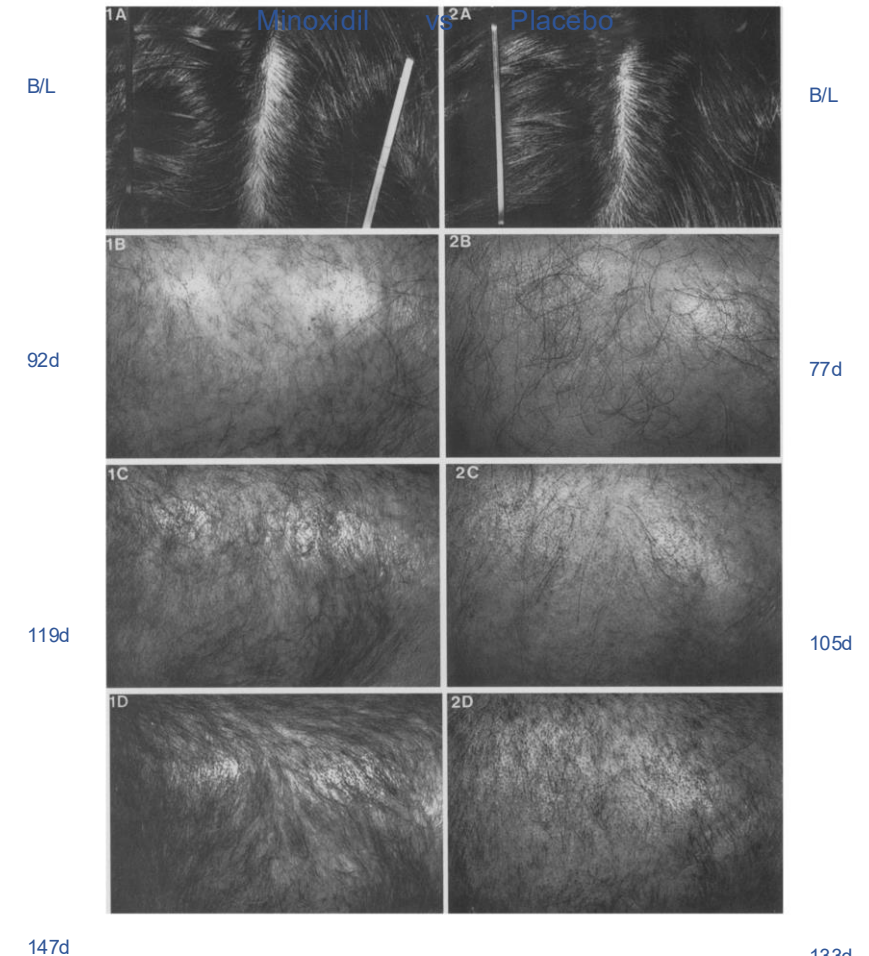




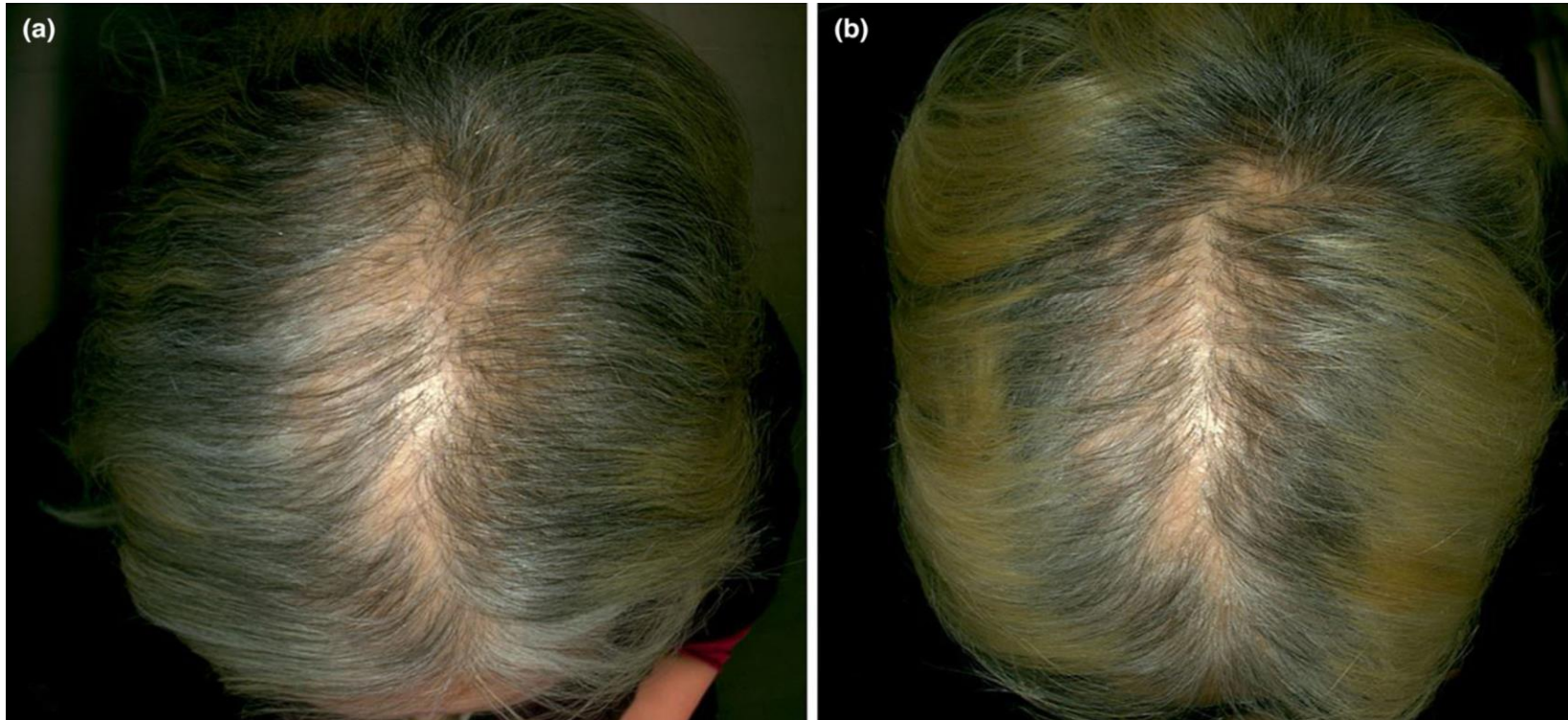
# Minoxidil Shortens the Period of Baldness

- Minoxidil shortened period of baldness by avg 50.2 days
- Does not prevent alopecia

J Am Acad Dermatol 1996;35:74-8.



# Minoxidil May Help Appearance Scarring GVHD by Increasing Background Hair Density



Baseline and after 12 mo of oral minoxidil in scarring hair loss

Gallo. J Eur Acad Dermatol  
Venereol. 2023 Jan;37(1):



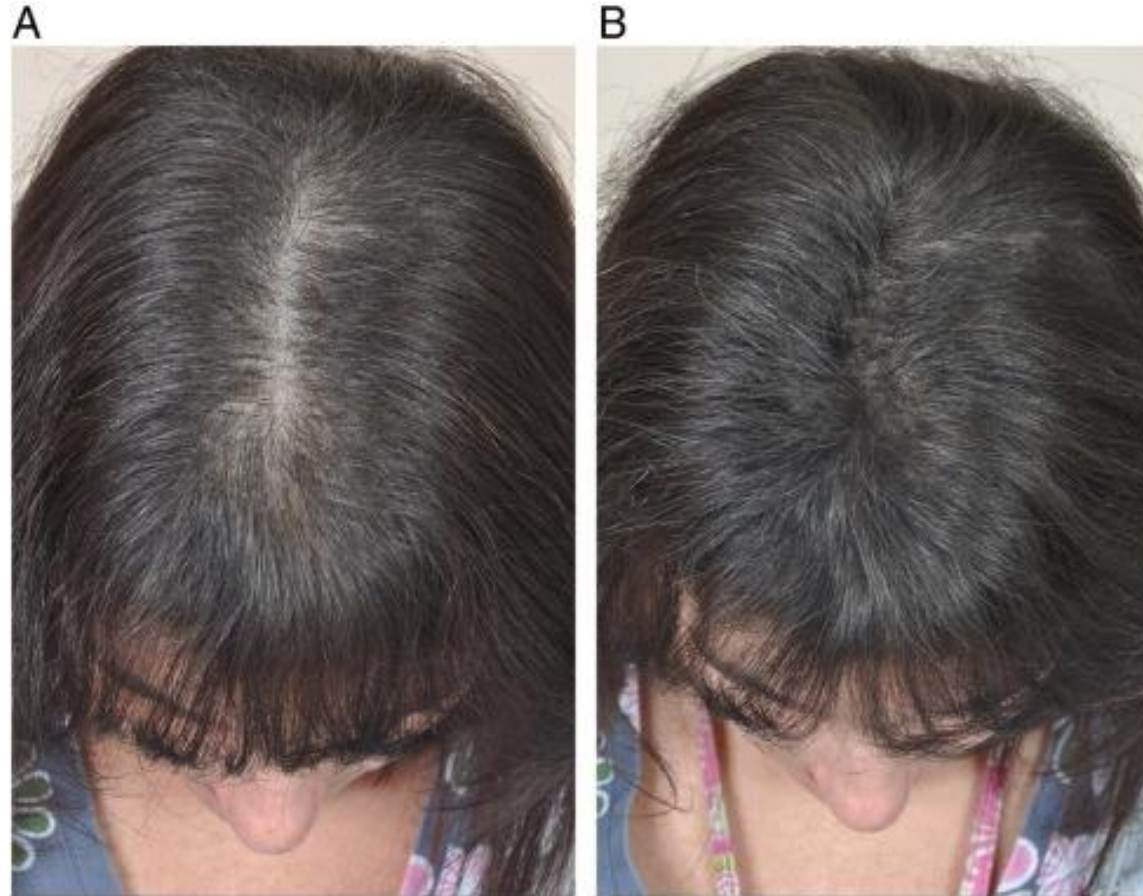


# Hair Care When You Have GVHD of the Scalp

- Wash and condition your hair every 2 – 4 days
- Use a shampoo and a cream rinse or hair conditioner
- When you brush or comb your hair, start at the ends. Use a soft-bristle brush, a comb, or your fingers.
- Use over-the-counter antifungal shampoo or prescription ketoconazole shampoo for dandruff/scale

# Pigmented Concealing Powders Can Camouflage Hair Thinning

- Powders
- Lotions
- Sprays

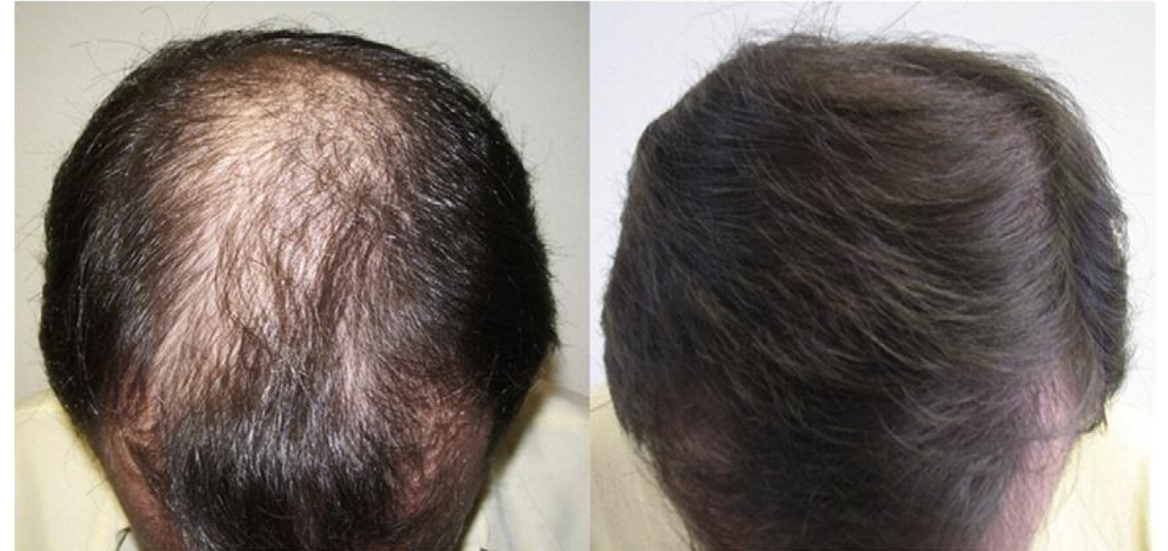

Saed. Int J Womens Dermatol. 2017 Feb 16;3(1 Suppl):S75-S80.



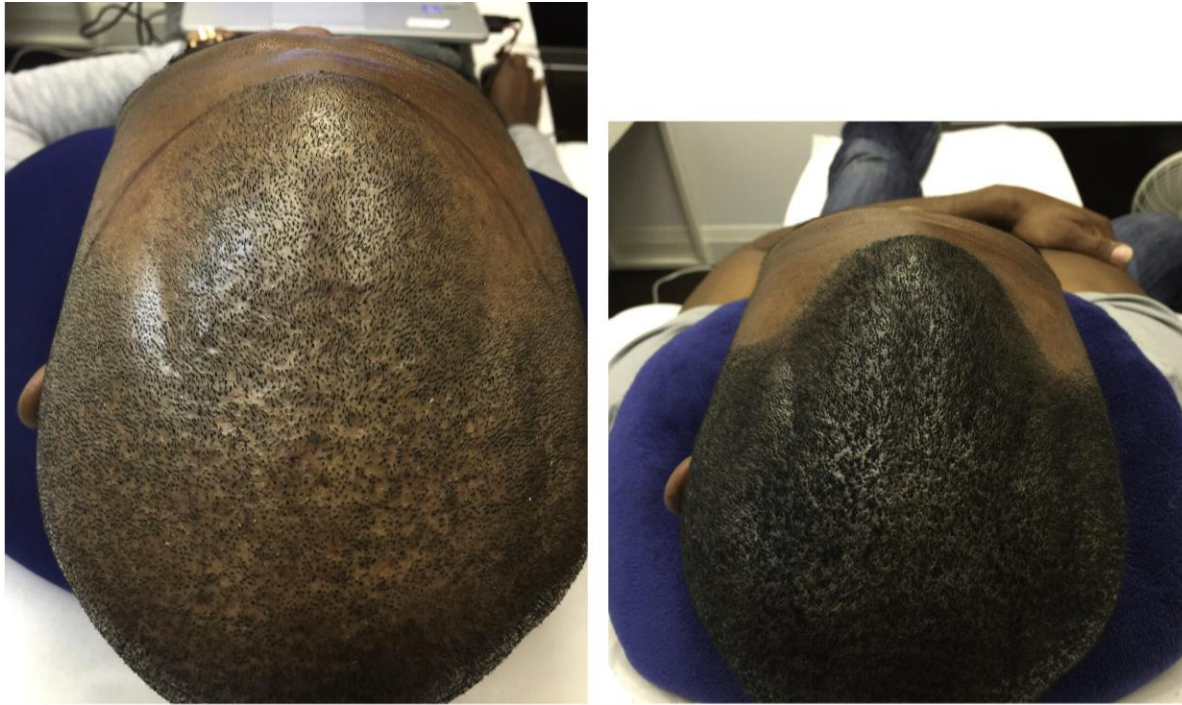# Hair Transplantation May Be Used Once GVHD is Inactive

- Advantages
  - Effective and permanent
  - Performed under local anesthesia
- Disadvantages
  - Risk of scalp swelling, bleeding, and minor infections
  - Risk of unnatural-looking hair
  - Creation of donor site scar
  - Expensive



Saed. Int J Womens Dermatol. 2017 Feb 16;3(1 Suppl):S75-S80.

# Micropigmentation Recreates Appearance of Hair Follicles



- Advantages
  - Relatively permanent
  - Resembles pores on a scalp
- Disadvantages
  - Risk of infection from the procedure
  - Risk of allergy to pigment
  - Natural hair must be dyed to match pigment
  - May need touchups over time

Saed. Int J Womens Dermatol. 2017 Feb 16;3(1 Suppl):S75-S80.



# SUMMARY

- Acute GVHD of the skin presents as a maculopapular rash
- Chronic GVHD may affect the skin, hair, or nails
- Many treatments are available that improve quality of life
- Notify your care team if you develop signs or symptoms of skin, hair, or nail GVHD
- **TIP:** In the age of telehealth, always document any new rashes with photos!



# Thank you!



# Questions?



**Alina Markova, MD**  
**Memorial Sloan Kettering**  
**Cancer Center**



# Let Us Know How We Can Help You

**Visit our website:** [bmtinfonet.org](http://bmtinfonet.org)

**Email us:** [help@bmtinfonet.org](mailto:help@bmtinfonet.org)

**Phone:** 888-597-7674 or 847-433-3313

